



# Multidirectional Shoulder Instability With Bone Loss and Prior Failed Latarjet Procedure: Treatment With Fresh Distal Tibial Allograft and Modified T-Plasty Open Capsular Shift

Liam A. Peebles, B.A., Zachary S. Aman, B.A., Fletcher R. Preuss, B.S.,  
Brian T. Samuelsen, M.D., M.B.A., Tyler J. Zajac, M.S., A.T.C., O.T.C.,  
Mitchell I. Kennedy, B.S., and Matthew T. Provencher, M.D., C.A.P.T., M.C., U.S.N.R.

**Abstract:** Recurrent multidirectional shoulder instability (MDI) is a challenging clinical problem, particularly in the setting of connective tissue diseases, and there is a distinct lack of literature discussing strategies for operative management of this unique patient group. These patients frequently present with significant glenoid bone loss, patulous and abnormal capsulolabral structures, and a history of multiple failed arthroscopic or open instability procedures. Although the precise treatment algorithm requires tailoring to the individual patient, we have shown successful outcomes in correcting recurrent MDI in the setting of underlying connective tissue disorders by means of a modified T-plasty capsular shift and rotator interval closure in conjunction with distal tibial allograft bony augmentation. The purpose of this Technical Note was to describe a technique that combines a fresh distal tibial allograft for glenoid bony augmentation with a modified T-plasty capsular shift and rotator interval closure for the management of recurrent shoulder MDI in patients presenting with Ehlers-Danlos syndrome or other connective tissue disorders after failed Latarjet stabilization.

Recurrent multidirectional shoulder instability (MDI) is a difficult clinical problem and becomes even more challenging in the face of connective tissue diseases (CTDs) such as Ehlers-Danlos syndrome. Patients with hyperlaxity present with recurrent, sometimes voluntary subluxation or dislocation events and abnormal anatomy. One should expect patulous capsular tissue and likely labral insufficiency.

Conversely, MDI without hyperlaxity is more likely to present with anterior and/or posterior capsulolabral pathology<sup>1,2</sup> in addition to bony lesions. Traditional anterior stabilization procedures depend on tightening capsular tissue and re-creating the labral bumper, but in patients with CTDs, this may not sufficiently restore stability or stretching may occur over time.<sup>3</sup>

Bony augmentation procedures such as a distal tibial allograft (DTA) procedure, iliac crest autograft procedure, or Latarjet procedure increase the articular surface area and lessen the reliance on the patient's abnormal soft tissues.<sup>4-6</sup> The use of a DTA avoids graft-site morbidity, provides a cartilage interface for glenohumeral articulation,<sup>5,7</sup> and shows similar clinical outcomes to the Latarjet procedure.<sup>8</sup> In addition, because it is an allograft, DTA can be used in a patient with a history of a failed Latarjet procedure.

Although bony procedures provide inherent stability, soft-tissue management remains critical in patients with connective tissue disorders. Altchek et al.<sup>9</sup> described a modified capsular shift technique, termed the "T-plasty," in which the anterior capsule is shifted on its medial (glenoid) attachment, simultaneously reducing anteroinferior capsular laxity and reducing the Bankart

From the Steadman Philippon Research Institute (L.A.P., Z.S.A., M.I.K., M.T.P.), Vail, Colorado; University of Virginia School of Medicine (F.R.P.), Charlottesville, Virginia; and The Steadman Clinic (T.J.Z., B.T.S., M.T.P.), Vail, Colorado, U.S.A.

The authors report the following potential conflicts of interest or sources of funding: M.T.P. receives royalties from Arthrex and is a consultant for Arthrex and Joint Research Foundation. Full ICMJE author disclosure forms are available for this article online, as [supplementary material](#).

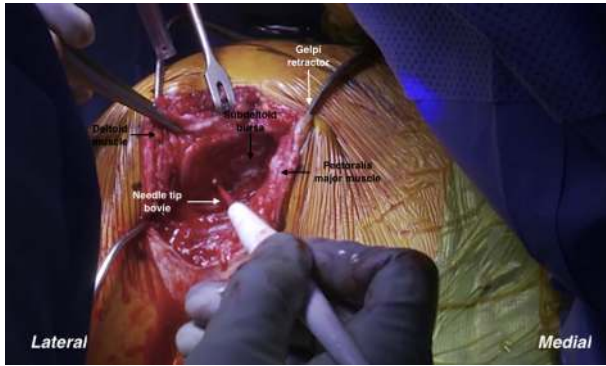
Received November 8, 2018; accepted January 6, 2019.

Address correspondence to Matthew T. Provencher, M.D., C.A.P.T., M.C., U.S.N.R., The Steadman Clinic, 181 W Meadow Dr, Ste 400, Vail, CO 81657, U.S.A. E-mail: [mprovencher@thesteadmanclinic.com](mailto:mprovencher@thesteadmanclinic.com)

© 2019 by the Arthroscopy Association of North America. Published by Elsevier. This is an open access article under the CC BY-NC-ND license (<http://creativecommons.org/licenses/by-nc-nd/4.0/>).

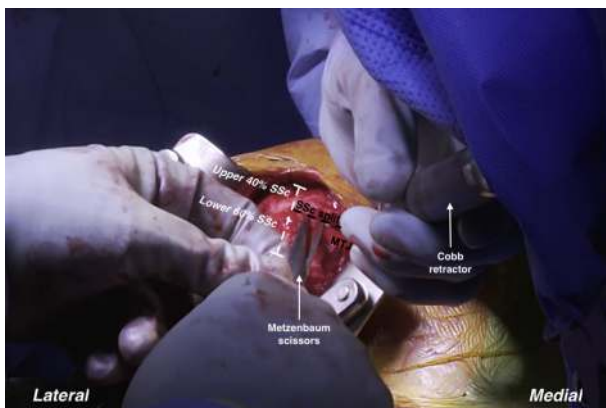2212-6287/181346

<https://doi.org/10.1016/j.eats.2019.01.002>



**Fig 1.** Careful dissection is carried through the deltopectoral interval of the right shoulder using Metzenbaum and Mayo scissors and a needle-tip Bovie device (Bovie Medical, Clearwater, FL) for a gentle Cobb dissection. A Gelpi retractor is used to provide further visualization of the subscapularis that underlies the subdeltoid bursa.

lesion on the anterior glenoid margin. Rotator interval closure (RIC) has also been used to successfully augment surgical treatment for MDI.<sup>2,10,11</sup> The open technique of Harryman et al.<sup>12</sup> imbricates and reinforces the coracohumeral ligament and superior glenohumeral ligament, tightening the rotator interval by approximately 1 cm. In patients with hyperlaxity due to connective tissue disorders, these techniques can be used effectively in combination to improve shoulder stability. The purpose of this Technical Note was to describe a technique that combines a DTA for glenoid bony augmentation with capsular T-plasty and RIC for the treatment of recurrent MDI in patients with Ehlers-Danlos syndrome or other connective tissue disorders after a failed Latarjet procedure (Video 1).



**Fig 2.** The subscapularis (SSc) of the right shoulder is split with a No. 15 blade scalpel and Metzenbaum scissors at the junction of the upper 40% and lower 60% of the tendon. The split is developed medially to the level of the musculotendinous junction (MTJ) to accommodate a T-plasty capsular shift.

## Surgical Procedure

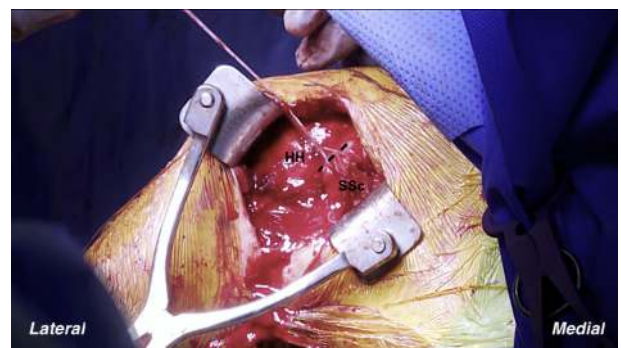### Patient Positioning and Diagnostic Arthroscopy

After the patient undergoes induction with general anesthesia and is placed in the beach-chair position, a standard arthroscopy is performed to fully assess the spectrum of intra-articular pathology. Particular attention must be given to the anterior glenoid to determine the amount of bone loss, capsular tissue quality, integrity of the glenolabral attachment, and presence or absence of cartilage lesions. In the setting of a failed Latarjet procedure, the surgeon should expect extensive scar tissue and altered anatomy in the subacromial space and rotator interval. Arthroscopic debridement should focus on defining the anatomy within the rotator interval.

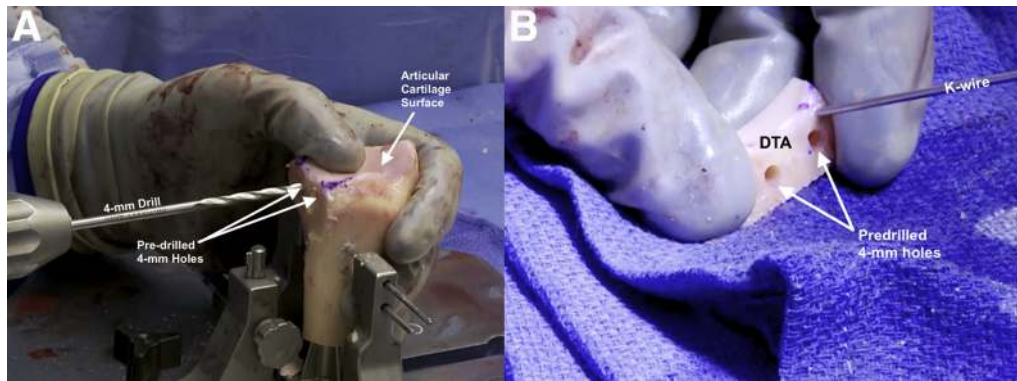
### Open Approach

An open incision is made in the area of the prior surgical incision, ideally from just lateral to the coracoid to just lateral to the axillary fold to allow for adequate exposure. Careful dissection is carried through the deltopectoral interval using Metzenbaum and Mayo scissors and gentle Cobb dissection (Fig 1). The cephalic vein should be preserved when possible and retracted laterally to increase the ease of glenoid exposure. Dissection continues until the rolled, superior border of the subscapularis is identified.

In a case with a previous failed Latarjet procedure, it is critical to understand how the subscapularis was handled, as well as whether the coracoid bone block was placed through a subscapularis split or in some other fashion. Extra time must be taken to define the anatomy and identify and protect the musculocutaneous nerve, axillary nerve, and other important medial neurovascular structures. The subscapularis should be split with a No. 15 blade and Metzenbaum scissors at the junction of the upper 40% and lower



**Fig 3.** In the case of significantly abnormal anatomy, a subscapularis tendon (SSc) tenotomy can be performed to allow adequate exposure of the anterior capsule in the right shoulder. The inferior 3 cm of the tendon can be incised (dashed line), tagged with SutureTape, and reflected off the humeral head (HH).



**Fig 4.** (A) By use of the distal tibial allograft workstation, the graft is irrigated and cut sequentially into the appropriate dimensions. (B) Two 4-mm holes are drilled parallel to the cartilage surface of the distal tibial allograft (DTA) in preparation for a lag technique. (K-wire, Kirschner wire.)

60% of the tendon (Fig 2). The split should be developed medially to the level of the musculotendinous junction to accommodate a T-plasty capsular shift. Laterally, the inferior 3 cm of the subscapularis and capsular leaflet is separated and tagged with SutureTape (Arthrex, Naples, FL) in a V-fashion. If the anatomy is significantly abnormal, a subscapularis peel or tenotomy may be performed to allow for adequate exposure and should be repaired later (Fig 3).

### Glenoid Preparation

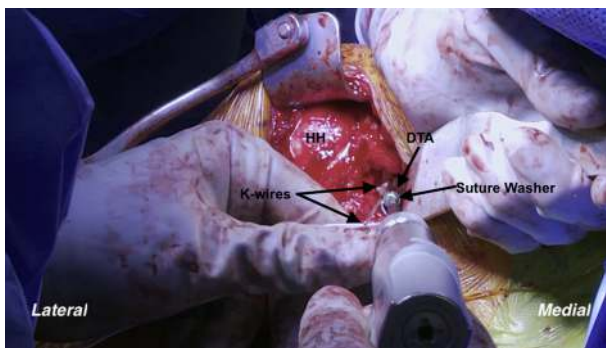
A Fukuda retractor is gently placed into the joint to visualize the anterior aspect of the glenoid. Hardware, screws, anchors, and suture from any previous procedure can then be removed. The capsule should be carefully dissected off the anterior glenoid, and a forked anterior glenoid retractor should be placed to protect the medial structures. The anterior surface of the glenoid can then be prepared with an osteotome and a high-speed 4.0-mm round burr down to healthy

bleeding bone. A power rasp is used to produce a flat surface 90° perpendicular to the glenoid fossa. Once the glenoid is fully prepared, the DTA can then be prepared on the back table.

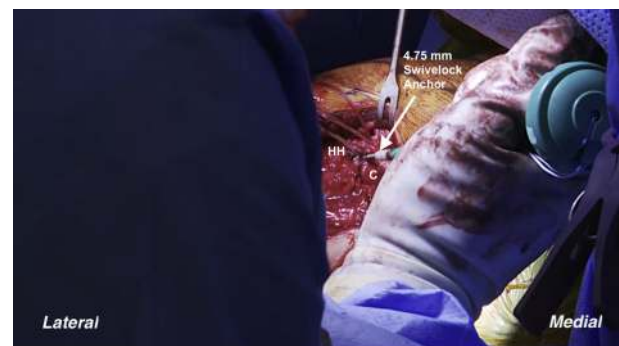### DTA Preparation and Insertion

Preoperative planning with computed tomography imaging will provide information regarding the approximate size of graft necessary to restore the bony anatomy. By use of the DTA workstation, the graft is irrigated and cut sequentially into the appropriate dimensions. Two 4-mm holes are drilled parallel to the cartilage surface of the DTA in preparation for a lag technique (Fig 4). If the surgeon chooses, the graft can be soaked for several minutes in a basin of platelet-rich plasma.

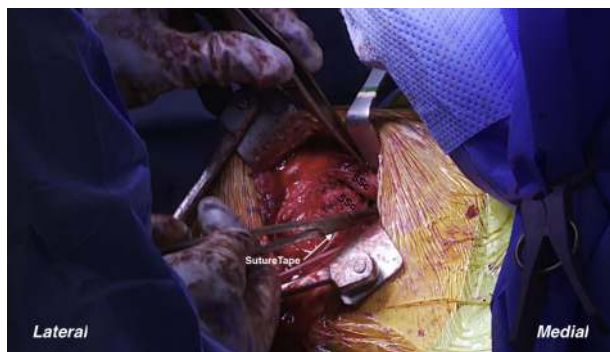The DTA is then temporarily fixed onto the flat surface of the anterior glenoid with the use of 2 Kirschner wires placed carefully alongside, but not within, the predrilled holes, ensuring that the cartilage of the graft is flush with the cartilage of the glenoid (Fig 5). The drill holes in the glenoid are created in line with the predrilled holes in the DTA. Two 4-mm bicortical



**Fig 5.** The distal tibial allograft (DTA) is temporarily fixed with 2 Kirschner wires (K-wires) alongside the predrilled holes to the glenoid of the right shoulder to ensure that the graft is placed flush with the glenoid articular cartilage. Holes are then drilled through the predrilled holes in the DTA. Two 4-mm compression screws with suture washers are placed until adequate fixation is achieved. (HH, humeral head.)



**Fig 6.** Two 4.75-mm Swivelock anchors are placed at the cartilage-capsular junction of the right humeral head (HH) to shift the previously tagged inferior capsular leaflet superiorly. (C, anterior capsule.)



**Fig 7.** The right subscapularis tendon (SSc) is repaired with 2 SwiveLock anchors and then over-sewn into its anatomic position with SutureTape. The dashed line indicates the subscapularis split.

compression screws with suture washers are placed until adequate fixation and compression of the graft are obtained. The sutures from the suture washers are subsequently used to repair the inferior leaflet of the capsule.

### Modified T-Plasty Capsular Shift, Subscapularis Repair, and RIC

For the T-plasty capsular shift, two 4.75-mm SwiveLock anchors (Arthrex) should be placed at the cartilage-capsular junction of the humeral head to shift the previously tagged inferior capsular leaflet approximately 8 mm superiorly (Fig 6). The subscapularis can then be repaired with 2 additional SwiveLock anchors and over-sewn into its anatomic position with SutureTape (Fig 7). The capsular portion of the rotator interval is closed with SutureTape in a pants-over-vest horizontal fashion. Skin and subcutaneous tissues are closed in routine fashion. Advantages and disadvantages are summarized in Table 1, and pearls and pitfalls of the complete surgical technique are summarized in Table 2.

### Postoperative Rehabilitation

The joint should be immobilized in a sling for approximately 6 to 8 weeks to allow healing of the capsule and subscapularis. The next 4 weeks should focus on both passive and active-assisted range of motion (ROM). Active ROM should wait until week 12 to prevent stretching of the repair; isometric exercises should be coupled with ROM for muscle stimulation (neuromuscular electrical stimulation may be used at this time). Strengthening occurs during weeks 14 to 16; progressive advancement through this phase over a period of 4 to 6 months is optimal, beginning with scapular stabilization, which will aid in reducing pain and improving movement (low-row exercises and muscle-memory exercises). Finally, between 6 and 8 months, the patient can work on return to play while strengthening continues around the operative site.

## Discussion

This Technical Note highlights the multiple bony and soft-tissue procedures necessary to achieve stability for patients presenting with MDI and CTDs. In this case, a T-plasty capsular shift of the inferior capsule and an RIC were performed in addition to the DTA procedure. The presented treatment should be considered in the setting of significant anterior glenoid bone loss after failed arthroscopic and/or open stabilization procedures, particularly in the face of CTDs.

Glenoid bone loss of 15% or greater with recurrent instability is a relative indication for glenoid augmentation.<sup>6</sup> Although the Latarjet procedure is generally the gold standard, revision cases may warrant a fresh DTA procedure.<sup>13-15</sup> Furthermore, there is increasing concern for early onset of glenohumeral arthritis after Latarjet stabilization in the young, active patient population.<sup>6</sup> Literature pertaining to DTA augmentation in patients with glenoid bone loss suggests low rates of recurrent instability, high osseous incorporation with the native glenoid, and excellent clinical outcomes regarding overall postoperative pain and joint function.<sup>5,16,17</sup> In addition, the DTA procedure has the benefit of no donor-site morbidity combined with the ability to create a custom, anatomic fit relative to each patient's unique defect dimensions.

In conjunction with bony augmentation, the T-plasty serves to reduce the anterior and inferior capsular laxity and re-establish the attachment of the inferior glenohumeral ligament, whereas the RIC imbricates the tissue of the rotator interval, providing additional anterior soft-tissue restraint. Altchek et al.<sup>9</sup> first described the T-plasty modification to the Bankart procedure in 1991; they proposed a surgical methodology that allowed for simultaneous capsular shift and Bankart repair to correct symptomatic MDI. Excellent outcomes were reported in 95% of the patients; however, throwing ability did not fully return to preinjury levels. An RIC is indicated for recurrent MDI and has been shown to improve stability in cadaveric and clinical studies.<sup>2,12,18-21</sup>

It is important that we discuss the potential risks and limitations of the proposed technique. Although using a

**Table 1.** Advantages and Disadvantages

Advantages	
Symptomatic glenoid bone loss is augmented while the anatomy and anterior-posterior or inferior-superior stability are restored.	
Graft-site morbidity is circumvented.	
An adequate cartilage interface for glenohumeral articulation is provided.	
A capsular repair to allograft, as well as a modified T-plasty capsular shift, is allowed.	
Disadvantages	
Allograft availability is variable, and allograft is difficult to acquire in some circumstances.	
The cost is increased when using allograft.	

**Table 2.** Pearls and Pitfalls**Pearls**

A forked anterior glenoid retractor should be used during dissection of the capsule to protect the medial structures. Preoperative CT imaging can aid in approximation of graft sizing, which should be confirmed intraoperatively. The graft should be copiously irrigated to remove pre-existing marrow contents; soaking in platelet-rich plasma prior to fixation may facilitate healing and graft incorporation.

**Pitfalls**

Graft preparation prior to intraoperative sizing can reduce conformity, ultimately reducing the success of the transplant. At fixation, failing to check for a flush transition between the graft and the cartilage of the glenoid can leave the shoulder at risk of future complications.

CT, computed tomography.

DTA circumvents the need for a fresh glenoid allograft, which is in much higher demand, DTA availability is variable and DTA may still be difficult to acquire in some circumstances. Moreover, if proper measures are not taken to accurately size the allograft based on preoperative and intraoperative templating, the patient may be at a greater risk of failed graft incorporation and recurrent instability. Finally, the surgeon must take care not to over-tighten the capsule during the T-plasty capsular shift. If the inferior leaflet of the capsule is translated too far superiorly or the subscapularis is not returned to its anatomic position, the patient may experience glenohumeral stiffness and limited ROM.

This Technical Note describes a combination of evidence-based bony and soft-tissue procedures that can help manage the challenging patient with recurrent MDI in the setting of Ehlers-Danlos syndrome or other connective tissue disorders. These patients typically present with a history of multiple failed surgical procedures, significant glenoid bone loss, and hyperlaxity. Although the precise treatment algorithm needs to be tailored to the individual patient, we have had success with the T-plasty capsular shift and RIC in conjunction with DTA bony augmentation. Recent literature and our experience with this surgical treatment have yielded positive results thus far; however, further research on the long-term patient outcomes must be performed to validate this surgical technique.

## References

- Longo UG, Rizzello G, Loppini M, et al. Multidirectional instability of the shoulder: A systematic review. *Arthroscopy* 2015;31:2431-2443.
- Gaskill TR, Taylor DC, Millett PJ. Management of multidirectional instability of the shoulder. *J Am Acad Orthop Surg* 2011;19:758-767.
- Armstrong MD, Smith B, Coady C, Wong IH. Arthroscopic anterior and posterior glenoid bone augmentation with capsular plication for Ehlers-Danlos syndrome with multidirectional instability. *Arthrosc Tech* 2018;7:e541-e545.
- Warner JJ, Gill TJ, O'Hollerhan JD, Pathare N, Millett PJ. Anatomical glenoid reconstruction for recurrent anterior glenohumeral instability with glenoid deficiency using an autogenous tricortical iliac crest bone graft. *Am J Sports Med* 2006;34:205-212.
- Provencher MT, Ghodadra N, LeClere L, Solomon DJ, Romeo AA. Anatomic osteochondral glenoid reconstruction for recurrent glenohumeral instability with glenoid deficiency using a distal tibia allograft. *Arthroscopy* 2009;25:446-452.
- Provencher MT, Frank RM, Golijanin P, et al. Distal tibia allograft glenoid reconstruction in recurrent anterior shoulder instability: Clinical and radiographic outcomes. *Arthroscopy* 2017;33:891-897.
- Millett PJ, Schoenahl JY, Register B, et al. Reconstruction of posterior glenoid deficiency using distal tibial osteoarticular allograft. *Knee Surg Sports Traumatol Arthrosc* 2013;21:445-449.
- Frank RM, Romeo AA, Richardson C, et al. Outcomes of Latarjet versus distal tibia allograft for anterior shoulder instability repair: A matched cohort analysis. *Am J Sports Med* 2018;46:1030-1038.
- Altchek DW, Warren RF, Skyhar MJ, Ortiz G. T-plasty modification of the Bankart procedure for multidirectional instability of the anterior and inferior types. *J Bone Joint Surg Am* 1991;73:105-112.
- Moon YL, Singh H, Yang H, Chul LK. Arthroscopic rotator interval closure by purse string suture for symptomatic inferior shoulder instability. *Orthopedics* 2011;34.
- Raynor MB, Horan MP, Greenspoon JA, Katthagen JC, Millett PJ. Outcomes after arthroscopic pancapsular capsulorrhaphy with suture anchors for the treatment of multidirectional glenohumeral instability in athletes. *Am J Sports Med* 2016;44:3188-3197.
- Harryman DT II, Sidles JA, Harris SL, Matsen FA III. The role of the rotator interval capsule in passive motion and stability of the shoulder. *J Bone Joint Surg Am* 1992;74:53-66.
- Boileau P, Mercier N, Roussanne Y, Thelu CE, Old J. Arthroscopic Bankart-Bristow-Latarjet procedure: The development and early results of a safe and reproducible technique. *Arthroscopy* 2010;26:1434-1450.
- Hovellius L, Sandstrom B, Sundgren K, Saebo M. One hundred eighteen Bristow-Latarjet repairs for recurrent anterior dislocation of the shoulder prospectively followed for fifteen years: Study I—Clinical results. *J Shoulder Elbow Surg* 2004;13:509-516.
- Flinkkila T, Sirnio K. Open Latarjet procedure for failed arthroscopic Bankart repair. *Orthop Traumatol Surg Res* 2015;101:35-38.
- Sayegh ET, Mascarenhas R, Chalmers PN, et al. Allograft reconstruction for glenoid bone loss in glenohumeral instability: A systematic review. *Arthroscopy* 2014;30:1642-1649.
- Provencher MT, LeClere LE, Ghodadra N, Solomon DJ. Postsurgical glenohumeral anchor arthropathy treated with a fresh distal tibia allograft to the glenoid and a fresh allograft to the humeral head. *J Shoulder Elbow Surg* 2010;19:e6-e11.
- Farber AJ, ElAttrache NS, Tibone JE, McGarry MH, Lee TQ. Biomechanical analysis comparing a traditional

- superior-inferior arthroscopic rotator interval closure with a novel medial-lateral technique in a cadaveric multidirectional instability model. *Am J Sports Med* 2009;37:1178-1185.
19. Provencher MT, Mologne TS, Hongo M, et al. Arthroscopic versus open rotator interval closure: Biomechanical evaluation of stability and motion. *Arthroscopy* 2007;23:583-592.
  20. Provencher MT, Peebles LA. Editorial commentary: Rotator interval closure of the shoulder continues to be a challenge in consensus on treatment. *Arthroscopy* 2018;34:3109-3111.
  21. Coughlin RP, Bullock GS, Shanmugaraj A, et al. Outcomes after arthroscopic rotator interval closure for shoulder instability: A systematic review. *Arthroscopy* 2018;34:3098-3108.e1.