



Chronic Instability and Pain of the Sternoclavicular Joint: Treatment With Semitendinosus Allograft to Restore Joint Stability

Liam A. Peebles, B.A., Zachary S. Aman, B.A., Fletcher R. Preuss, B.S.,
Brian T. Samuelsen, M.D., M.B.A., Tyler J. Zajac, M.S., A.T.C., O.T.C., Ravi B. Patel, M.D.,
and CAPT Matthew T. Provencher, M.D., M.C., U.S.N.R.

Abstract: Chronic instability of the sternoclavicular (SC) joint is a challenging clinical problem, particularly in a patient population for which nonoperative forms of treatment prove ineffective. Patients present after experiencing recurrent subluxation events and subsequent pain, which commonly result in increasing functional limitation. Recurrent SC joint instability of this nature can lead to damage of the SC joint cartilage and bone, and in cases of posterior subluxation or dislocation, damage to mediastinal structures. While the precise treatment algorithm requires tailoring to individual patients and their respective pathologies, we have demonstrated successful outcomes in correcting chronic SC joint instability by means of SC joint reconstruction with semitendinosus allograft, SC joint capsular reconstruction, and, in cases of arthritic damage, resection of a small portion of the degenerative component of the medial clavicle. The purpose of this Technical Note is to describe a technique that uses a semitendinosus allograft to stabilize the SC joint combined with a capsular reconstruction in patients who have previously failed nonoperative treatment methods.

The sternoclavicular (SC) joint, where the medial clavicle articulates with the manubrium, joins the upper limbs to the axial skeleton. The capsule surrounding the joint is reinforced by the interclavicular ligament superiorly, the costoclavicular ligament inferiorly, the anterior SC ligament, and the posterior SC ligament.¹ Strong ligamentous and capsular support renders the SC joint one of the least dislocated joints in the body.²⁻⁴

Traditionally, treatment of chronic SC joint instability or dislocation has focused on symptomatic relief, with an emphasis on pain control and activity modification.^{3,5} This differs starkly from the treatment of acute dislocation, which is typically managed with closed or open reduction and immobilization. While most patients with chronic instability can be managed nonoperatively, some cases are refractory to conservative management, with patients experiencing recurrent dislocations for years, leading to increasing pain and functional limitation. Long-term sequelae of chronic SC joint instability include damage to the SC joint cartilage and bone and in rare cases damage to mediastinal structures in cases of posterior subluxation or dislocation.^{3,5-9}

Surgical treatment by medial clavicle resection or figure-of-8 reconstruction has been reported, as well as treatment with intramedullary suture, internal fixation across the joint, or reinforcement with the subclavian tendon or sternocleidomastoid muscle.^{1,6,7,9-11} Of note, K-wire/pin fixation is associated with dangerous complications including wire and pin migrations or breakages, posing a risk to mediastinal structures.^{12,13} The purpose of this Technical Note is to describe our preferred technique to surgically treat a chronically unstable and symptomatic SC joint, consisting of SC joint reconstruction with semitendinosus allograft, SC

From the Steadman Philippon Research Institute (L.A.P., Z.S.A., M.T.P.) and the Steadman Clinic (B.T.S., T.J.Z., M.T.P.), Vail, Colorado; University of Virginia School of Medicine (F.R.P.), Charlottesville, Virginia; and Henry Ford Hospital, Department of Orthopaedic Surgery (R.B.P.), Detroit, Michigan, U.S.A.

The authors report the following potential conflicts of interest or sources of funding: M.T.P. receives support from Arthrex, the Joint Research Foundation, and SLACK. Full ICMJE author disclosure forms are available for this article online, as [supplementary material](#).

Received December 4, 2018; accepted February 16, 2019.

Address correspondence to Matthew T. Provencher, M.D., Capt., M.C., U.S.N.R., Orthopedic Shoulder and Knee Surgeon, Steadman Philippon Research Institute, The Steadman Clinic, 181 W Meadow Dr, Ste 400, Vail, CO 81657, U.S.A. E-mail: mprovencher@thesteadmanclinic.com

© 2019 by the Arthroscopy Association of North America. Published by Elsevier. This is an open access article under the CC BY-NC-ND license (<http://creativecommons.org/licenses/by-nc-nd/4.0/>).

2212-6287/181472

<https://doi.org/10.1016/j.eats.2019.02.006>

joint capsular reconstruction, and resection of the SC joint.

Surgical Procedure

Approach to SC Joint

Following induction by the anesthesia team, the patient is prepped and draped in the beach chair position and the procedure begins with an approximately 8-cm incision through the skin and subcutaneous tissue, centered over the SC joint (Fig 1). Dissection is carried down sharply to the anterior joint capsule, which is frequently deficient in the setting of chronic instability. Self-retaining retractors aid visualization. A horizontal incision is made in the SC joint capsule remnant with a no. 15 blade scalpel, exposing the intra-articular disc. The pectoralis and deltoid fascia are carefully dissected off of the medial clavicle and lateral sternum, and a periosteal elevator is used to elevate the periosteum anteriorly, superiorly, and inferiorly in preparation for later graft passage. Small Hohmann retractors are placed on the superior and inferior borders of the clavicle to protect the posterior neurovascular structures and to mobilize the clavicle anteriorly. The intra-articular disc and cartilaginous surfaces of the SC joint may now be examined, and hypertrophied capsule and degenerated disc are excised (Fig 2). In the setting of significant chondromalacia, a rongeur is used to remove medial clavicular osteophytes, and an oscillating saw may be used to resect up to 3 to 5 mm of the medial clavicle. Care is taken to remove as minimal of an amount of the medial clavicle as possible. The clavicle is then contoured to minimize any subcutaneous prominence. The dissection on the clavicular side should be carried lateral enough to

accommodate the most lateral bone tunnel, which will be placed 25 mm from the joint.

Allograft and SC Joint Preparation

A semitendinosus allograft is prepared on the back table with locking sutures at each end. A guide pin is introduced unicortically through the anterior surface of the clavicle in the midline, 25 mm lateral to the SC joint. This pin is then overdrilled unicortically only with a cannulated 6-mm drill to allow access to the intramedullary canal (Fig 3). Next the same guide pin for the 6-mm cannulated drill is introduced into the intramedullary canal from the medial side of the clavicle (Fig 4). The pin is advanced in the intramedullary space 25 mm laterally, until it can be seen in the base of the previously created hole in the anterior clavicle, and then overdrilled with the 6-mm drill. This creates a bone tunnel through which a looped suture is shuttled with a Hewson suture passer for eventual allograft passage. The looped end should be coming out of the anterior drill hole. Two 6-mm unicortical bone tunnels are created on the sternum about 15 mm medial to the lateral border of the SC joint and about 15 mm apart superior to inferior. The 6-mm drill is then used to drill 2 separate 15-mm tunnels from the lateral aspect of the sternum until they connect with the previously drilled unicortical sternal holes. Looped sutures are shuttled through the 2 sternal tunnels, such that the looped ends are exiting into the SC joint.

Allograft Passage and Fixation

The prepared semitendinosus graft is brought onto the field and is first passed around the clavicle, just lateral to the anterior drill hole. Care must be taken to pass the

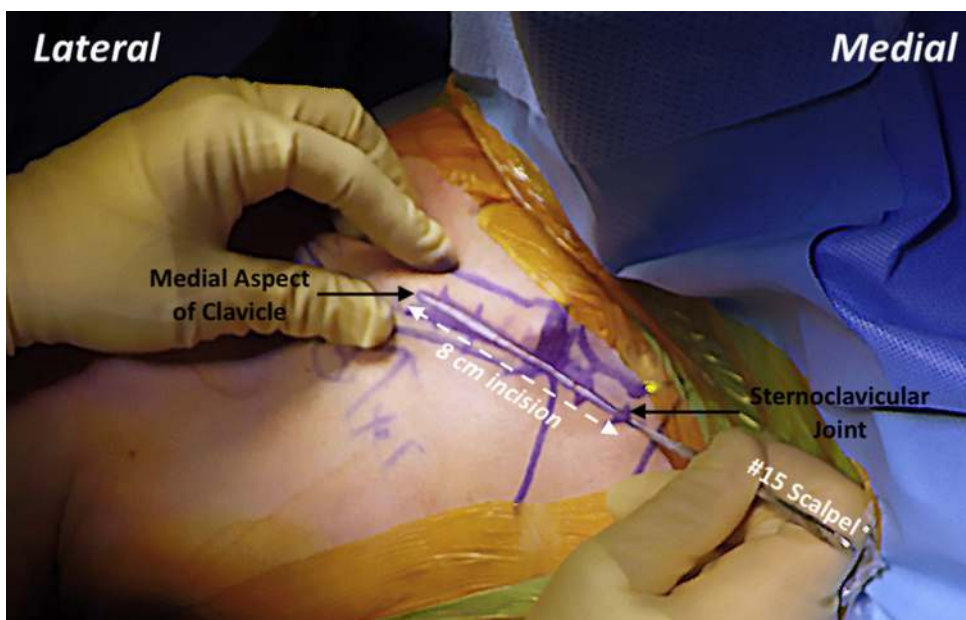
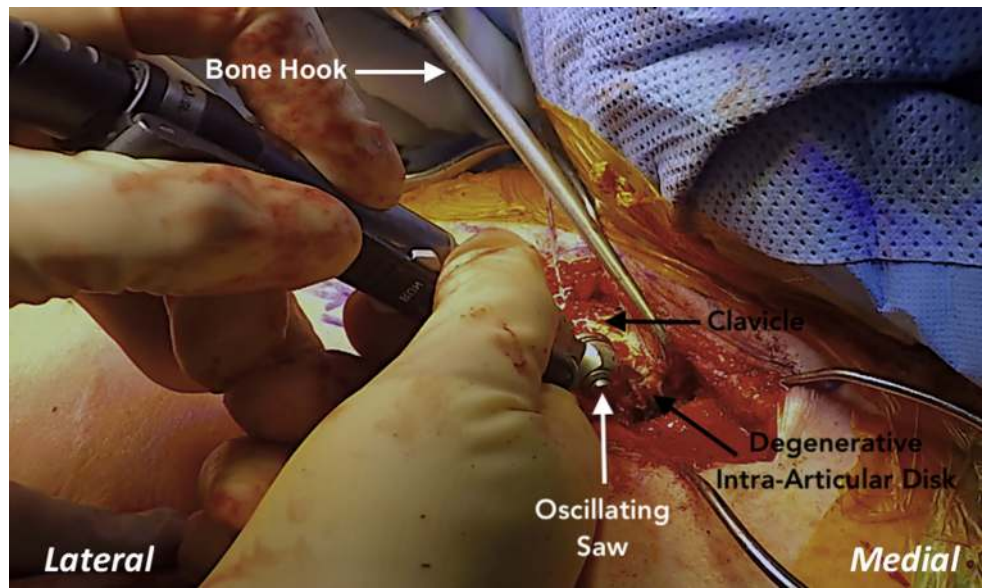


Fig 1. Right shoulder, beach chair position. An incision of approximately 8 cm is made with a no. 15 blade scalpel through the skin and subcutaneous tissue, centered over the sternoclavicular joint, and the dissection is carried down sharply to the anterior joint capsule.

Fig 2. Right shoulder, beach chair position. Hypertrophied capsule and degenerated intra-articular disc are excised from the proximal clavicle with a rongeur and an oscillating saw. A periosteal elevator and self-retaining retractors are used to mobilize and expose the clavicle, providing excellent visualization.



graft immediately along the bone to avoid damage to the posterior structures. A curved forceps or other cerclage passing device may be used to aid with this step. The graft ends should then be pulled even and tightened around the clavicle in a luggage loop fashion. Next the previously passed shuttling stitch is used to pass the 2 ends of the allograft through the anterior clavicle hole and intramedullary canal, into the SC joint (Fig 5). Care is taken to ensure equal lengths of the graft exit the clavicle. The limbs of the allograft are then passed into each sternal drill hole and brought out anteriorly. The graft is then tensioned while the clavicle

is manually held in its anatomic position, which reduces and stabilizes the SC joint. While holding tension on the graft limbs, 2 biocomposite interference screws (PEEK Bio-Tenodesis; Arthrex, Naples, FL) are advanced into each sternal bone tunnel to secure the graft (Fig 6). The excess ends of the graft are then crossed back laterally over the SC joint to reconstruct the capsule and are sutured in place with suture tape in locking fashion (Fig 7). The graft ends are sutured to themselves as they cross the SC joint as well as to any remaining capsular tissue. The construct is then tested manually to evaluate whether the reconstruction

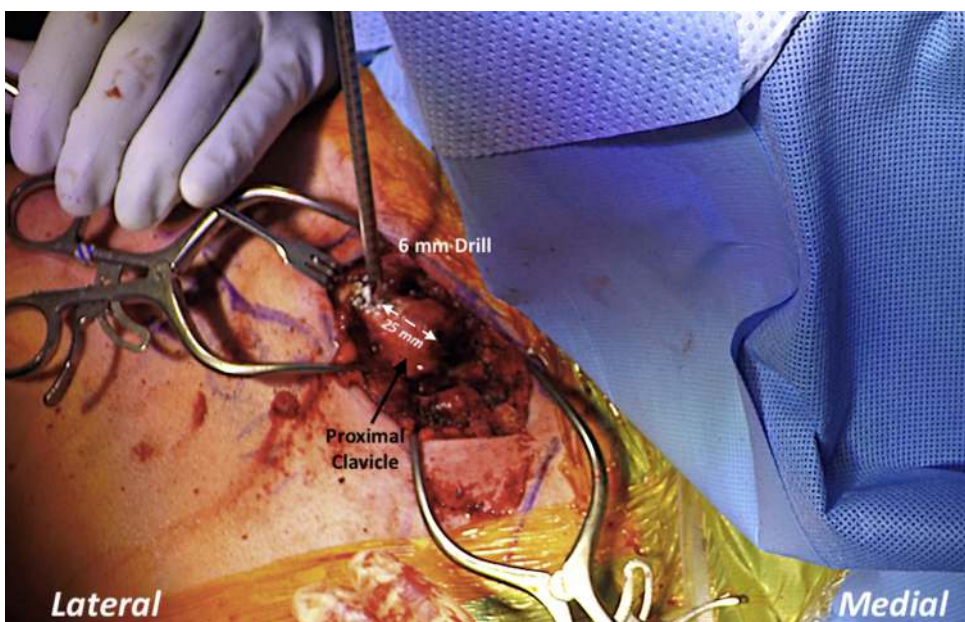


Fig 3. Right shoulder, beach chair position. A guide pin is introduced unicortically through the anterior surface of the clavicle in the midline, 25 mm lateral to the sternoclavicular joint, which is then overdrilled unicortically only with a cannulated 6-mm drill to allow access to the intramedullary canal.

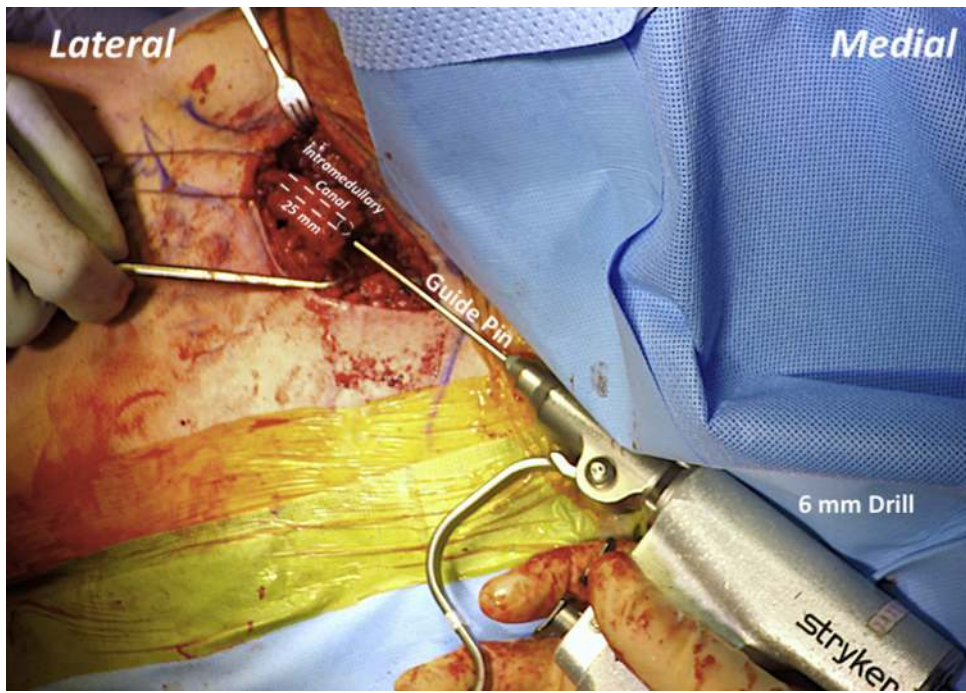


Fig 4. The guide pin for the 6-mm cannulated drill is introduced into the intramedullary canal from the medial side of the clavicle, which is advanced through the intramedullary space 25 mm laterally, until it can be seen in the base of the previously created hole in the anterior clavicle, and then overdrilled with the 6-mm drill.

successfully reduces anterior translation of the clavicle. The terminal ends of the graft may then be incorporated into the closure of the pectoralis and deltoid fascia. The wound should be thoroughly irrigated, and the skin and subcutaneous tissue closed in a layered fashion. The patient is placed in a padded abduction sling prior to being awoken from anesthesia. Advantages and disadvantages as well as pearls and pitfalls of the complete surgical technique are summarized in [Tables 1](#) and [2](#), respectively.

Postoperative Rehabilitation

Immobilization of the SC joint is essential to allowing the repair to heal and strengthen prior to starting movement. The time frame for immobilization is between 6 and 8 weeks. Movement of any kind can be detrimental to healing; therefore, no scapular retraction or protraction should occur in the first 8 weeks. Following this, it is just as important to start movement to regain full range of motion. When rehabilitating the SC joint, passive, active-assisted, and active

Fig 5. Right shoulder, beach chair position. A previously passed shuttling stitch is used to pass the 2 ends of the semitendinosus allograft through the anterior clavicle hole and intramedullary canal in a luggage loop fashion into the sternoclavicular (SC) joint. Once the graft is secured, this will pull the clavicle medially toward the sternum and restore stable SC joint anatomy.

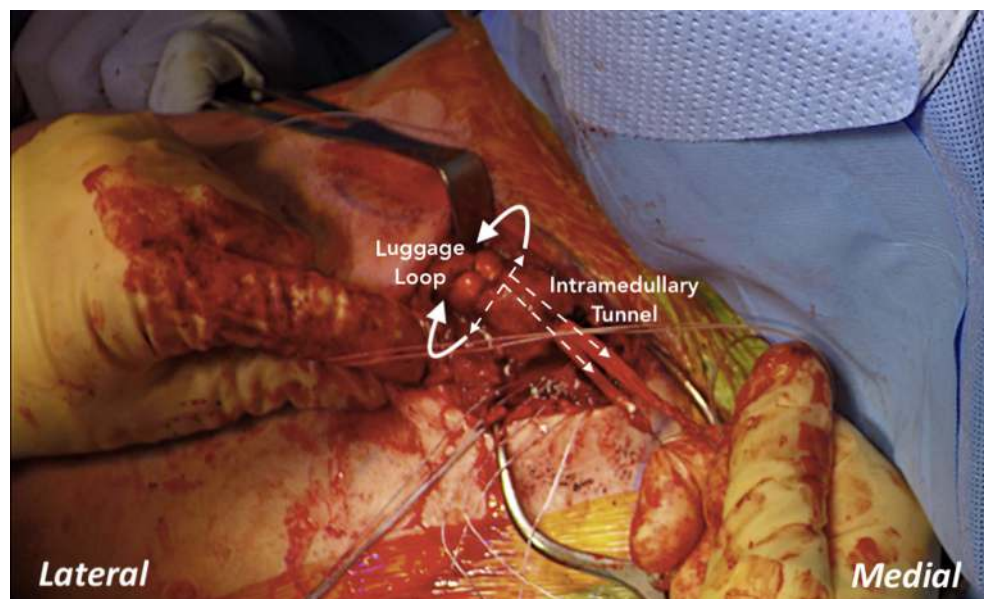
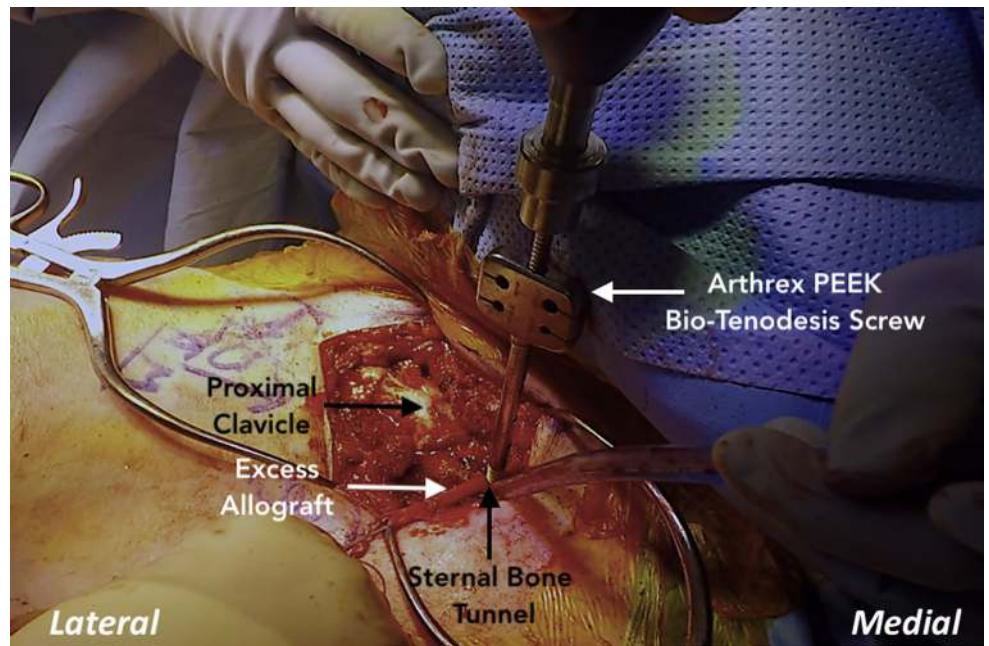


Fig 6. Right shoulder, beach chair position. While holding tension on each of the allograft limbs, 2 biocomposite interference screws (Arthrex PEEK Bio-Tenodesis) are advanced into each sternal bone tunnel, to secure the graft. The stability of the construct should be tested for any residual laxity of the semitendinosus allograft or sternoclavicular joint.



range of motion can all be started simultaneously. However, internal rotation of the shoulder should be limited to 90° at the side or to the stomach only. Stretching is also allowed at this time; however, internal rotation and the cross-arm stretch should be avoided until 3 months postoperatively. Finally, isometric strengthening should be done during the 6- to 8-week postoperative period. Initial resistance

strengthening can begin around 8 weeks and progress from there with more aggressive strengthening occurring around 12 weeks. Return to full activity occurs around 5 to 6 months. During the entire postoperative rehabilitation period, patients should avoid downward pulling forces, heavy lifting, and traction to the shoulder. These can injure the repair and cause major setbacks and even failures.

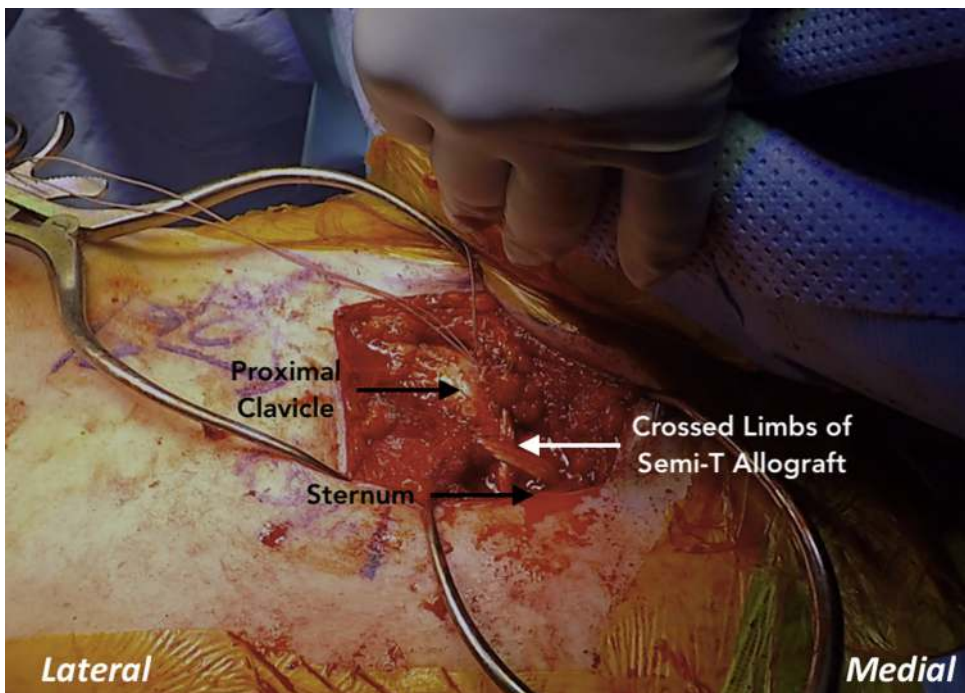


Fig 7. Right shoulder, beach chair position. The excess ends of the semitendinosus allograft are finally crossed back laterally over the sternoclavicular (SC) joint and are sutured in place with suture tape in locking fashion, which serves to reconstruct the capsule of the SC joint.

Table 1. Advantages and Disadvantages

Advantages	Disadvantages
Open procedure provides optimal visualization for anatomic reconstruction and protection of neurovasculature structures.	Allograft availability is variable and difficult to acquire in some circumstances.
Figure-of-8 reconstruction restores native biomechanics of the sternoclavicular joint.	Increased cost of using allograft; this may be avoided by using gracilis or palmaris longus autograft.

Discussion

This Technical Note describes SC joint resection and the use of a modified figure-of-8 technique with semitendinosus allograft to address a case of chronic SC joint instability with concomitant capsular insufficiency. Improvements in surgical technique and increased provider awareness of SC joint pathology have led to an increase in the number of patients being treated surgically for chronic SC instability. Ligamentous reconstruction has gained favor in recent years given the reduced risk of neurovascular injury compared with screw or K-wire fixation. Variable treatment algorithms and surgical techniques have been described in the literature for the management of this condition, which has led to a lack of consistency in treatment¹⁴⁻¹⁷; most notably, surgeons often differ in their choice of the type of tendon graft to use, whether to use autograft or allograft, and the specific reconstruction technique. A recent biomechanical study of a figure-of-8 reconstruction technique with semitendinosus graft found excellent strength with this reconstruction technique,⁴ and it thus served as the basis of the current proposed technique.

Despite the heterogeneity in treatment choice, the available literature has reported generally positive clinical outcomes for ligamentous SC joint reconstructions in appropriately selected patients. A 2011 systematic review by Glass et al.¹² of 251 dislocations in 24 case series found that 62% of chronic dislocations (44 total patients) were treated with open reduction, and 33 of those patients had excellent/good outcomes while 11 had fair/poor outcomes.¹² Overall

functional outcomes following nonoperative or operative treatment were better for patients with acute dislocations than they were for patients with chronic dislocations. Other small case series and case report studies have reported full return to activities following surgery for acute and chronic SC joint instability.^{1,5,7,16-19}

The treatment of chronic SC joint instability is challenging due to the presence of scar tissue and degenerative changes of the intra-articular disc and cartilage. Resection of the medial clavicle is typically indicated when the SC joint has degenerated due to prolonged instability.⁹ Recent studies have reported positive outcomes with patient pain reduction, improvement in function, and high return to play at up to 2 years of follow-up.¹⁵ In chronic cases, SC joint reconstruction should also be performed when posterior subluxation is present, which places mediastinal structures at risk for serious injury.

The figure-of-8 technique has been reported to have satisfactory outcomes for patients with chronic SC joint instability when using a gracilis or palmaris longus autograft at a minimum of 2 years of follow-up.²⁰ However, most studies evaluating outcomes for patients with chronic SC joint instability have been limited to heterogeneity of type of graft used and small sample sizes.^{1,5,6}

This Technical Note describes a combination of evidence-based osseous and soft tissue procedures, consisting of SC joint reconstruction with semitendinosus allograft, SC joint capsular reconstruction, and potential resection of the SC joint to correct a chronically unstable and symptomatic SC joint. In our experience, the treatment of chronic SC joint instability using a modified figure-of-8 technique with a semitendinosus allograft provides excellent stability, reduction in pain, and improvement in patient function. In addition, concurrent treatment with proximal clavicle resection further addresses pain due to cartilage degeneration and should be considered when indicated. We acknowledge that although recent literature and our experience with this surgical treatment have yielded positive patient outcomes thus far, homogenous and long-term clinical outcome studies are required to fully evaluate the

Table 2. Pearls and Pitfalls

Pearls	Pitfalls
Care should be taken to protect the local neurovascular structures when preparing the medial clavicle with the oscillating saw.	It is crucial to hold tension on the graft limbs when securing them with the interference screws. Failure to do so will result in only a partial reduction of the medial clavicle.
Preoperative computed tomography imaging and radiographs can aid in approximating translation of the medial clavicle, which should be confirmed intraoperatively.	Upon fixation, failure to assess the stability of the construct for any residual laxity can leave the sternoclavicular joint at risk for future complications.
The excess graft limbs are crossed and advanced laterally over the sternoclavicular joint to serve as a capsular reconstruction.	

efficacy of this treatment for patients with chronic instability.

References

- Guan JJ, Wolf BR. Reconstruction for anterior sternoclavicular joint dislocation and instability. *J Shoulder Elbow Surg* 2013;22:775-781.
- Renfree KJ, Wright TW. Anatomy and biomechanics of the acromioclavicular and sternoclavicular joints. *Clin Sports Med* 2003;22:219-237.
- de Jong KP, Sukul DM. Anterior sternoclavicular dislocation: A long-term follow-up study. *J Orthop Trauma* 1990;4:420-423.
- Spencer EE, Kuhn JE, Huston LJ, Carpenter JE, Hughes RE. Ligamentous restraints to anterior and posterior translation of the sternoclavicular joint. *J Shoulder Elbow Surg* 2002;11:43-47.
- Bae DS, Kocher MS, Waters PM, Micheli LM, Griffey M, Dichtel L. Chronic recurrent anterior sternoclavicular joint instability: Results of surgical management. *J Pediatr Orthop* 2006;26:71-74.
- Wirth MA, Rockwood CA Jr. Acute and chronic traumatic injuries of the sternoclavicular joint. *J Am Acad Orthop Surg* 1996;4:268-278.
- Castropil W, Ramadan LB, Bitar AC, Schor B, de Oliveira D'Elia C. Sternoclavicular dislocation—reconstruction with semitendinosus tendon autograft: A case report. *Knee Surg Sports Traumatol Arthrosc* 2008;16:865-868.
- Jaggard MK, Gupte CM, Gulati V, Reilly P. A comprehensive review of trauma and disruption to the sternoclavicular joint with the proposal of a new classification system. *J Trauma* 2009;66:576-584.
- Martetschlager F, Warth RJ, Millett PJ. Instability and degenerative arthritis of the sternoclavicular joint: A current concepts review. *Am J Sports Med* 2014;42:999-1007.
- Booth CM, Roper BA. Chronic dislocation of the sternoclavicular joint: An operative repair. *Clin Orthop Relat Res* 1979;(140):17-20.
- Morell DJ, Thyagarajan DS. Sternoclavicular joint dislocation and its management: A review of the literature. *World J Orthop* 2016;7:244-250.
- Glass ER, Thompson JD, Cole PA, Gause TM 2nd, Altman GT. Treatment of sternoclavicular joint dislocations: A systematic review of 251 dislocations in 24 case series. *J Trauma* 2011;70:1294-1298.
- Thut D, Hergan D, Dukas A, Day M, Sherman OH. Sternoclavicular joint reconstruction: A systematic review. *Bull NYU Hosp Joint Dis* 2011;69:128-135.
- Wang D, Camp CL, Werner BC, Dines JS, Altchek DW. Figure-of-8 reconstruction technique for chronic posterior sternoclavicular joint dislocation. *Arthrosc Tech* 2017;6:e1749-e1753.
- Katthagen JC, Tahal DS, Menge TJ, Horan MP, Millett PJ. Minimum 2-year outcomes and return to sport following resection arthroplasty for the treatment of sternoclavicular osteoarthritis. *J Shoulder Elbow Surg* 2017;26:e37-e43.
- Tytherleigh-Strong G, Pecheva M, Titchener A. Treatment of first-time traumatic anterior dislocation of the sternoclavicular joint with surgical repair of the anterior capsule augmented with internal bracing. *Orthop J Sports Med* 2018;6. 2325967118783717.
- Quayle JM, Arnander MW, Pennington RG, Rosell LP. Artificial ligament reconstruction of sternoclavicular joint instability: Report of a novel surgical technique with early results. *Tech Hand Up Extrem Surg* 2014;18:31-35.
- Rockwood CA Jr, Groh GI, Wirth MA, Grassi FA. Resection arthroplasty of the sternoclavicular joint. *J Bone Joint Surg Am* 1997;79:387-393.
- Adamcik S, Ahler M, Gioutsos K, Schmid RA, Kocher GJ. Repair of sternoclavicular joint dislocations with FiberWire((R)). *Arch Orthop Trauma Surg* 2017;137:341-345.
- Bak K, Fogh K. Reconstruction of the chronic anterior unstable sternoclavicular joint using a tendon autograft: Medium-term to long-term follow-up results. *J Shoulder Elbow Surg* 2014;23:245-250.