

# An Expert Consensus Statement on the Management of Large Chondral and Osteochondral Defects in the Patellofemoral Joint

Jorge Chahla,\* MD, PhD, Betina B. Hinckel, MD, PhD, Adam B. Yanke, MD, PhD, Jack Farr, MD, and Metrics of Osteochondral Allografts (MOCA) Group

*Investigation performed at Midwest Orthopaedics at Rush and the Rush University Medical Center, Chicago, Illinois, USA*

**Background:** Cartilage lesions of the patellofemoral joint constitute a frequent abnormality. Patellofemoral conditions are challenging to treat because of complex biomechanics and morphology.

**Purpose:** To develop a consensus statement on the functional anatomy, indications, donor graft considerations, surgical treatment, and rehabilitation for the management of large chondral and osteochondral defects in the patellofemoral joint using a modified Delphi technique.

**Study Design:** Consensus statement.

**Methods:** A working group of 4 persons generated a list of statements related to the functional anatomy, indications, donor graft considerations, surgical treatment, and rehabilitation for the management of large chondral and osteochondral defects in the patellofemoral joint to form the basis of an initial survey for rating by a group of experts. The Metrics of Osteochondral Allografts (MOCA) expert group (composed of 28 high-volume cartilage experts) was surveyed on 3 occasions to establish a consensus on the statements. In addition to assessing agreement for each included statement, experts were invited to propose additional statements for inclusion or to suggest modifications of existing statements with each round. Predefined criteria were used to refine statement lists after each survey round. Statements reaching a consensus in round 3 were included within the final consensus document.

**Results:** A total of 28 experts (100% response rate) completed 3 rounds of surveys. After 3 rounds, 36 statements achieved a consensus, with over 75% agreement and less than 20% disagreement. A consensus was reached in 100.00% of the statements relating to functional anatomy of the patellofemoral joint, 88.24% relating to surgical indications, 100.00% relating to surgical technical aspects, and 100.00% relating to rehabilitation, with an overall consensus of 95.5%.

**Conclusion:** This study established a strong expert consensus document relating to the functional anatomy, surgical indications, donor graft considerations for osteochondral allografts, surgical technical aspects, and rehabilitation concepts for the management of large chondral and osteochondral defects in the patellofemoral joint. Further research is required to clinically validate the established consensus statements and better understand the precise indications for surgery as well as which techniques and graft processing/preparation methods should be used based on patient- and lesion-specific factors.

**Keywords:** patellofemoral; cartilage; osteochondral; allograft; consensus; Delphi

Cartilage lesions of the patellofemoral joint are particularly common; however, surgery is not indicated in many cases, especially when they are asymptomatic.<sup>11,20,26,58</sup> Chondral and osteochondral injuries of the patellofemoral joint present several challenges for their treatment, as the morphology of the patella and trochlea can have wide variability between patients. In addition to its unique anatomy, the

patellofemoral joint also experiences very high loads with daily activities, including 1.3 times the body weight (BW) during level ambulation, 3.3 times BW during stair ambulation, 5.6 times BW during running, and up to 7.8 times BW during a deep knee bend or squat.<sup>28</sup> Other factors that add additional complexity include excessive patellar malalignment, maltracking, patella alta or baja, and trochlear dysplasia, among others.<sup>3,4,12,26,32,59</sup>

When indicated, multiple surgical options exist for large symptomatic defects. Matrix-induced autologous chondrocyte implantation (MACI) and osteochondral

The Orthopaedic Journal of Sports Medicine, 8(3), 2325967120907343  
DOI: 10.1177/2325967120907343  
© The Author(s) 2020

This open-access article is published and distributed under the Creative Commons Attribution - NonCommercial - No Derivatives License (<https://creativecommons.org/licenses/by-nc-nd/4.0/>), which permits the noncommercial use, distribution, and reproduction of the article in any medium, provided the original author and source are credited. You may not alter, transform, or build upon this article without the permission of the Author(s). For article reuse guidelines, please visit SAGE's website at <http://www.sagepub.com/journals-permissions>.

allograft transplantation (OCA) remain the most commonly utilized methods of treatment.<sup>12,45</sup> These treatments are used routinely in other compartments of the knee; however, the morphology, alignment, and biomechanics of the patellofemoral joint make some of these techniques particularly challenging. For example, the complex topography and variable anatomy of the patella and trochlea make OCA technically more demanding than autologous chondrocyte implantation (ACI) because of the need to match graft morphology to patient anatomy. As a result of this complexity, inferior outcomes have been reported with the treatment of symptomatic large patellofemoral lesions when compared with tibiofemoral cartilage treatments.<sup>12,24</sup> In addition, clinical studies, especially clinical trials, very often focus on the tibiofemoral joint, and the literature on cartilage restoration in the patellofemoral joint is much more limited.<sup>24,40,80</sup> For those reasons, significant debate remains regarding the indications and

specifics of each technique for the surgical treatment of patellofemoral chondral defects.

Despite the growing body of literature on this topic, a standardized algorithm is lacking, leading to persistent controversy in the surgical treatment of large symptomatic patellofemoral cartilage injuries. In such instances, an expert consensus can be synthesized using a modified Delphi method. This allows for the development of a group-based consensus. The Delphi method provides several advantages over other group-based processes, including the preservation of participant anonymity that can reduce the effects of dominant participants.<sup>39</sup> Additionally, Delphi consensus statements conducted at a distance have been demonstrated to be as reliable as face-to-face panels,<sup>93</sup> with further advantages of greater participant flexibility.<sup>42</sup> For the abovementioned reasons, the purpose of this study was to develop a Delphi consensus statement on the functional anatomy, indications, donor graft

---

\*Address correspondence to Jorge Chahla, MD, PhD, Midwest Orthopaedics at Rush, 1611 West Harrison Street, Suite 300, Chicago, IL 60612, USA (email: jorge.chahla@rushortho.com).

All authors are listed in the Authors section at the end of this article.

Final revision submitted November 24, 2019; accepted December 3, 2019.

One or more of the authors has declared the following potential conflict of interest or source of funding: J.C. has received research support and consulting fees from Arthrex, Conmed, and Smith & Nephew. B.B.H. has received research support from Arthrex and educational support from Arthrex and Elite Orthopaedics. A.B.Y. has received research support from Arthrex, Orthogenesis, Medwest, and Vericel; educational support from Arthrex, Medwest, and Smith & Nephew; and consulting fees from Aastrom Biosciences, JRF Ortho, Olympus, PatientIQ, Smith & Nephew, and Sparta Biomedical. J.F. has received consulting fees from Osiris Therapeutics, Zimmer Biomet, ISTO Technologies, Ceterix Orthopaedics, Biomet, Genzyme, MedShape, and Sanofi-Aventis; has received speaking fees from Arthrex and Zimmer Biomet; has received royalties from Arthrex, DePuy, Organogenesis, Springer, and Thieme Medical Publishers; and has stock/stock options in MedShape and Ortho Regenerative Technologies. W.D.B. has received consulting fees from Arthrex, DePuy, Insight Medical, JRF Ortho, OrthAlign, and Smith & Nephew; has received royalties from DePuy, Smith & Nephew, and Zimmer Biomet; and has stock/stock options in Insight Medical, Moximed, and OrthAlign. B.J.C. has received research support from Aesculap/B. Braun, Arthrex, and Regentis Biomaterials; has received educational support from Medwest; has received consulting fees from Acumed, Anika Therapeutics, Arthrex, Bioventus, Flexion Therapeutics, Geistlich Pharma, Genzyme, Pacira Pharmaceuticals, Regentis Biomaterials, Smith & Nephew, Vericel, and Zimmer Biomet; has received speaking fees from Arthrex, Carticept Medical, LifeNet Health, and Pacira Pharmaceuticals; has received hospitality payments from GE Healthcare; has received royalties from Arthrex, DJO, Elsevier, and *Operative Techniques in Sports Medicine*; and has stock/stock options in BandGrip, Ossio, and Regentis Biomaterials. D.C.C. has received research support from Histogenics, JRF Ortho, Moximed, and Zimmer Biologics and consulting fees from ArthroSurface, DePuy, Histogenics, JRF Ortho, and Moximed. J.E.F. has received research support from Arthrex and Smith & Nephew; educational support from Linvatec, Peerless Surgical, and Zimmer Biomet; and consulting fees and speaking fees from Smith & Nephew. A.G. has received research support from Aesculap/B. Braun, Arthrex, DePuy, Euraxia Pharmaceuticals, Musculoskeletal Transplant Foundation, Ossur, and Smith & Nephew; consulting fees from Collagen Solutions, Olympus, Ossur, and Smith & Nephew; speaking fees from Conmed Linvatec, Ossur, and Smith & Nephew; and royalties from Smith & Nephew. A.H.G. has received research support from JRF Ortho and Vericel; consulting fees from Aesculap, Geistlich Pharma, Genzyme, JRF Ortho, Moximed, Smith & Nephew, and Vericel; speaking fees from Aastrom Biosciences, LifeNet Health, and Vericel; and royalties from Organogenesis. S.G. has received educational support from Arthrex and Goode Surgical and honoraria from Vericel. A.E.G. has received consulting fees, speaking fees, and royalties from Zimmer Biomet and has stock/stock options in Intellijoint Surgical. D.G.J. has received research support from Genzyme and Sanofi-Aventis; has received educational support from Arthrex; has received consulting fees from Aastrom Biosciences, Acumed, AmnioX Medical, DePuy/Medical Device Business Services, Flexion, Genzyme, Vericel, and Zimmer Biomet; has received speaking fees from Arthrex, Conmed Linvatec, Flexion, Genzyme, Mitek, Musculoskeletal Transplant Foundation, TissueTech, Vericel, and Zimmer Biomet; and is a board or committee member of the Musculoskeletal Transplant Foundation. A.J.K. has received research support from Aesculap/B. Braun, Arthrex, Ceterix Orthopaedics, and Histogenics; has received consulting fees from Arthrex, DePuy, JRF Ortho, and Vericel; has received speaking fees from Arthrex; and is a board or committee member of the Musculoskeletal Transplant Foundation. C.L. has received honoraria from ArthroSurface; consulting fees from Aastrom Biosciences, Genzyme, JRF Ortho, Samumed, Sanofi-Aventis, Vericel, and Zimmer Biomet; and speaking fees from Vericel. B.R.M. has received consulting fees from Arthrex, BioMarin Pharmaceutical, DePuy, and Exactech; speaking fees from Arthrex; and royalties from Arthrex. R.M. has received research support from Arthrex and DJO, has received educational support from Arthrex, has received speaking fees from Arthrex, has received royalties from Zimmer Biomet, and has stock/stock options in AlignMed. T.S.M. has received research support from JRF Ortho, educational support from Arthrex, consulting fees from JRF Ortho and MicroAire Surgical Instruments, and speaking fees from JRF Ortho. J.D.P. has received research support from Ossur, Sanofi-Aventis, and Vericel; consulting fees from JRF Ortho; and speaking fees from DePuy. M.T.P. has received consulting fees from Arthrex and JRF Ortho (AlloSource), speaking fees from Arthrex, and royalties from Arthrex and SLACK. S.A.R. has received consulting fees from Flexion, has received speaking fees from Smith & Nephew, has received honoraria from Fidia Pharma, has received royalties from Zimmer Biomet, and has stock/stock options in Ortho Regenerative Technologies. O.S. has received research support from DePuy and consulting fees from Zimmer Biomet. S.L.S. has received consulting fees and research support from Arthrex Inc; is a paid consultant for Ceterix Orthopaedics, CONMED Linvatec, Flexion Therapeutics, GLG Consulting, JRF Ortho, Moximed, Olympus, Vericel, Linvatec, and RTI Surgical; has received hospitality payments from Linvatec and Smith & Nephew; and has received a grant (indirect) from DJO. E.D.S. has received research support from CartiHeal, Fidia Pharma, and NuTech; consulting fees from Arthrex, Fidia Pharma, Flexion, JRF Ortho, Organogenesis, Smith & Nephew, and Vericel; speaking fees from Arthrex, Organogenesis, and Vericel; and royalties from Jaypee Brothers Medical Publishers. C.J.W. has received consulting fees from ArthroSurface and Smith & Nephew and speaking fees from Arthrex, ArthroSurface, and Smith & Nephew. R.J.W. has received research support from Histogenics; has received consulting fees from Arthrex, JRF Ortho, and Lipogems; has received speaking fees from Arthrex; has received royalties from Arthrex; and has stock/stock options in CyMedica Orthopedics, Gramercy Extremity Orthopedics, Pristine Surgical, and RecoverX. AOSSM checks author disclosures against the Open Payments Database (OPD). AOSSM has not conducted an independent investigation on the OPD and disclaims any liability or responsibility relating thereto.

TABLE 1  
Summary of Results at the End of Each Survey Round in the Delphi Process

Delphi Round	No. of Responses	Total No. of Statements Included in Survey	% of Statements Reaching a Consensus	No. of New Statements	No. of Modifications Suggested
1	35	35	69.0	0	0
2	35	35	82.0	0	8
3	35	36	95.5	1	4

considerations, treatment, and rehabilitation for the management of large chondral and osteochondral defects in the patellofemoral joint.

## METHODS

### Study Design

A working group of 4 individuals (J.C., B.B.H., A.B.Y., J.F.) was responsible for facilitating the development of a consensus using modified Delphi techniques as previously described.<sup>14</sup> A comprehensive list of statements was generated under 5 categories: functional anatomy, surgical indications, donor graft considerations for osteochondral allografts, surgical technical aspects, and rehabilitation concepts for the management of large chondral and osteochondral defects in the patellofemoral joint. The Metrics of Osteochondral Allografts (MOCA) expert group was surveyed on 3 occasions to establish a consensus on the inclusion/exclusion of each statement.

### Identification of Statements for Inclusion in the First-Round Survey

Potential statements for inclusion in the first-round survey were prepared by the working group on the basis of recently published studies, including systematic reviews and meta-analyses of patellofemoral joint cartilage treatment.<sup>15,35,69,80</sup> Online surveys were generated to allow respondents to vote whether statements should be included in an expert consensus document relating to the management of large chondral and osteochondral defects in the patellofemoral joint. There were 5 possible responses on a Likert<sup>53</sup> scale including “strongly agree,” “agree,” “neither agree nor disagree,” “disagree,” or “strongly disagree.” A free-text comment section was included to allow for suggested modifications or additional statements. The survey was piloted by 3 experts for face validity, understanding, and acceptability, resulting in minor modifications.

### Establishing Consensus Using Delphi Methods

Delphi methods were used to establish a group consensus on whether statements should be included in an expert consensus document relating to the management of large chondral and osteochondral defects in the patellofemoral joint.<sup>82</sup> A total of 28 experts were included based on their comprehensive and authoritative knowledge of the topic, having a known clinical practice that utilizes cartilage

restorative procedures for the patellofemoral joint (minimum of 30 cartilage cases per year), and having frequently published and/or lectured on the topic (>10 publications on patellofemoral chondral injuries). Experts were part of a previously established group (2016) of osteochondral allograft experts (MOCA group).

Experts participated in 3 rounds of surveys between February and April 2019 (Table 1). First-round surveys were analyzed, and participants were sent an anonymized summary of the results together with a second survey. In round 1, statements were categorized as “essential” and retained for round 2 if over 70% of respondents agreed and fewer than 20% disagreed. Statements not meeting these criteria were discarded or modified according to rater suggestions. The second-round survey also included any new statements suggested by experts in round 1. In round 2, participants were asked to rescore the statements and provide free-text comments. In round 2, responses were analyzed, retaining statements if over 70% of respondents agreed on their inclusion and fewer than 20% disagreed. Statements retained after round 2 were considered in round 3. Questionnaires were reanalyzed and the cycle repeated in round 3. For a consensus, defined a priori, statements were included in the final consensus document if over 75% of respondents agreed and fewer than 20% disagreed in the third-round Delphi survey (Table 2 and Figure 1).

## DISCUSSION

The most important finding of this study was that a consensus among high-volume experts on the management of patellofemoral chondral injuries was reached on the majority of the statements (95.5%). Surgical indications were the most controversial topic with the highest disagreement reported. Specifically, the Delphi method failed to reach a consensus for indications for OCA versus ACI. This is most likely because of the lack of clinical studies comparing the 2 techniques, which results in surgeons’ decisions being based largely on personal experience. However, overall strong agreement was reached for all categories including functional anatomy of the patellofemoral joint, surgical indications, donor graft considerations for osteochondral allografts, surgical technical aspects, and rehabilitation concepts.

### Functional Anatomy

The experts felt that the patella and trochlea were both high-loading (weightbearing) components of the knee. To

TABLE 2  
Levels of Agreement and Disagreement in the Statements Included in the Third-Round Survey<sup>a</sup>

Section Subheadings and Final Statements	% Disagreement	% Agreement
Functional anatomy		
The patella and trochlea are both high-loading (weightbearing) components of the knee. <sup>55</sup>	0.00	92.86
Surgical indications		
Factors that influence the timing and indications for surgery include cause, age, location, concomitant abnormality, range of motion, and patient expectations. <sup>66</sup>	0.00	100.00
OCA and ACI are valid treatments for large focal chondral injuries of the patella. <sup>35,37,63,76,88</sup>	3.57	89.29
OCA and ACI are valid treatments for large focal chondral injuries of the trochlea. <sup>13,35,63,76,88</sup>	3.57	92.86
Associated significant malalignment and/or maltracking should be addressed with osteotomy concomitantly or before the cartilage restoration procedure. <sup>25,29,35,70,73,76,87,92</sup>	0.00	96.43
Associated patellofemoral instability should be addressed with patellar stabilization procedures concomitantly or before the cartilage restoration procedure. <sup>35,46,81,85,89</sup>	3.57	96.43
Full patellar chondral resurfacing could be indicated in a young patient with subtotal cartilage loss of the patella. <sup>25,35,37,46,88</sup>	0.00	89.29
Uncontained lesions can be treated with OCA. <sup>13,37</sup>	3.57	85.71
Uncontained lesions can be treated with ACI as long as the membrane can be fixed to the bone through sutures/anchors. <sup>25,34,35</sup>	0.00	100.00
Bipolar lesions can be treated with OCA for both surfaces. <sup>5,16,46,57,64,85</sup>	3.57	82.14
Bipolar lesions can be treated with ACI for both surfaces when there is no significant joint space narrowing. <sup>25,34,35,61,63,76,88</sup>	7.14	85.71
In bipolar patellofemoral lesions, unloading osteotomy should be strongly considered when ACI is performed. <sup>7,35,78</sup>	0.00	96.43
In bipolar patellofemoral lesions, unloading osteotomy should be strongly considered when OCA is performed. <sup>7,78</sup>	3.57	82.14
Relative contraindications for OCA include end-stage osteoarthritis and very restricted range of motion. <sup>30</sup>	0.00	92.86
Relative contraindications for ACI include end-stage osteoarthritis and very restricted range of motion. <sup>27</sup>	0.00	96.43
OCA is preferred over ACI for patellofemoral conditions that involve uncontained lesions and significant bone abnormalities such as intralesional osteophytes; revision settings including prior failed microfracture, prior fracture malunion, significant subchondral bone edema, significant subchondral cyst formation; and bone loss due to fractures or osteochondritis dissecans fragment excision. <sup>21,31,36,38,60,79,b</sup>	3.57	67.86
ACI can be used in conditions that involve significant bone abnormalities with the "sandwich technique," bone grafting, and overlying ACI. <sup>62,75</sup>	0.00	85.71
ACI is preferred over OCA in lesions that include the central trochlear groove, the median patellar ridge, and multifocal lesions. <sup>18,35,80,b,c</sup>	28.57	35.71
Donor graft considerations for osteochondral allografts		
Fresh osteochondral grafts are preferred over cryopreserved grafts when available. <sup>19,47</sup>	0.00	100.00
Presurgical matching should be performed to avoid graft-recipient size mismatching for osteochondral allografts based on radiography with a sizing marker <sup>8,23</sup> and magnetic resonance imaging. <sup>8</sup>	0.00	92.86
Surgical technical aspects		
Osteochondral allografts should be implanted in <28 days to have adequate chondrocyte viability. <sup>2,6,95</sup>	0.00	96.43
The dowel technique is the preferred method for the treatment of focal chondral defects when using osteochondral allografts.	0.00	92.86
Ideally, matching areas from the donor graft are preferred. <sup>16,37</sup>	0.00	89.29
Preference should be given to matching cartilage surface topography and peripheral step-off over osseous mismatching. <sup>17,43,50,72,83,90</sup>	0.00	100.00
The ideal depth of the allograft should be limited to 6 to 10 mm depending on the size and location of the graft. <sup>91</sup>	0.00	100.00
Attempts should be made to remove all marrow elements utilizing pulse lavage or similar methods. <sup>44,58</sup>	0.00	96.43
Impaction of the graft should be avoided when possible, and the graft should be placed in a press-fit manner when contained. <sup>9,71</sup>	0.00	96.43
Supplemental fixation of an osteochondral allograft is needed only if the graft is unstable or full trochlear and/or patellar resurfacing is performed. <sup>10,13,37</sup>	0.00	100.00
When using ACI, one should not exceed the edges of the lesion. <sup>41</sup>	0.00	89.29
Suture fixation is not usually required for ACI unless the membrane is unstable after the addition of the sealant. <sup>25,34,35</sup>	0.00	82.14
Rehabilitation		
The mean survival rate of patellofemoral osteochondral allografts at 5 and 10 years is higher than 75%. <sup>13,37</sup>	0.00	78.57
Patient satisfaction is high, and clinical outcomes are improved in 70% to 80% of patients 10 years after patellofemoral ACI. <sup>63,69,76</sup>	0.00	89.29

(continued)

Table 2 (continued)

Section Subheadings and Final Statements	% Disagreement	% Agreement
A sequential staged rehabilitation program (range of motion, muscular endurance, strength, and power) is essential for a successful outcome. <sup>65</sup>	0.00	96.43
An early mobilization protocol is safe and should be implemented to avoid arthrofibrosis. <sup>13,37,63</sup>	0.00	96.43
Nonweightbearing range of motion is safe and desired if no associated osteotomy is performed. <sup>35,54</sup>	7.14	89.29
Progressive weightbearing, as tolerated, with a knee brace locked in full extension does not excessively load the patellofemoral joint and is safe if no associated osteotomy is performed. <sup>35,55,77</sup>	0.00	100.00

<sup>a</sup>ACI, autologous chondrocyte implantation; OCA, osteochondral allograft transplantation.

<sup>b</sup>Statements not reaching a consensus.

<sup>c</sup>Any implantation of cultured chondrocytes in a membrane; this includes all generations and membrane compositions such as Carticel, matrix-induced autologous chondrocyte implantation, ChondroCelect, Hyalograft C, and NeoCart, among others.

this point, Flynn and Soutas-Little<sup>28</sup> reported forces of 1.3 times BW during level ambulation, 3.3 times BW during stair ambulation, 5.6 times BW during running, and up to 7.8 times BW during a deep knee bend or squat. As a significant weightbearing surface, these symptomatic lesions often require an intervention. However, given the unique mechanics and morphology, surgical techniques have greater technical demand when applied to the patellofemoral joint compared with the femoral condyles.

## Indications

As loading areas, surgical treatment of symptomatic chondral defects in the patellofemoral joint should be considered when nonoperative measures fail. While the majority of experts agreed on most indication statements, 2 statements did not achieve agreement (indications of ACI vs OCA for the treatment of certain chondral defects). Several factors (cause, age, location, concomitant abnormalities, range of motion, and patient expectations) were considered important when deciding the timing and indications for surgery, even though the literature is conflicting on how those variables affect outcomes.<sup>15</sup> Evidence suggests that age, cause, and location likely do not affect outcomes, while female sex, lesions in the patella, large lesions, and bipolar chondral defects potentially lead to less optimal results.<sup>4</sup> Other factors such as concurrent malalignment, maltracking, and patellar instability should be carefully evaluated during the workup of patients with chondral lesions, as they were deemed of utmost importance by the expert panel (they should be corrected before or at the time of the cartilage repair procedure). The importance of correcting coexisting abnormalities and anatomic abnormalities was initially highlighted by Peterson et al.<sup>76</sup> These authors reported on 224 patients who underwent ACI, recognizing that patients with patellar lesions had less than optimal outcomes when compared with patients with lesions in the femoral condyles.<sup>11,74</sup> However, when selective tibial tuberosity osteotomy was performed, the improvement in patients with patellofemoral lesions was similar to that in patients with lesions in the femoral condyles.<sup>76</sup> Several authors later reported comparable results, acknowledging

the importance of correcting maltracking before or concurrently with the cartilage procedures.<sup>35,46,81,85,89</sup>

Both ACI and OCA were considered valid treatments for large chondral defects in the patella and trochlea except in cases of end-stage osteoarthritis and/or restricted range of motion (<100°-110°). While end-stage arthritis is a contraindication to cartilage repair, subtotal loss or bipolar lesions without significant joint space narrowing can be treated with ACI or OCA, especially in young patients.<sup>#</sup> The addition of unloading osteotomy can reduce joint surface pressures up to 30% and is recommended when treating those patients with bipolar lesions.<sup>7,35,78</sup> Even though the sandwich technique has been described in the treatment of bone lesions concomitantly with ACI, there was no agreement on its utilization, and OCA was preferred for cases that include intralesional osteophytes, revision including prior failed microfracture, prior fracture malunion, significant subchondral stress reactions also known as “bone edema,” significant subchondral cyst formation, and bone loss due to fractures or osteochondritis dissecans fragment excision.<sup>21,31,36,38,60,62,75,79</sup>

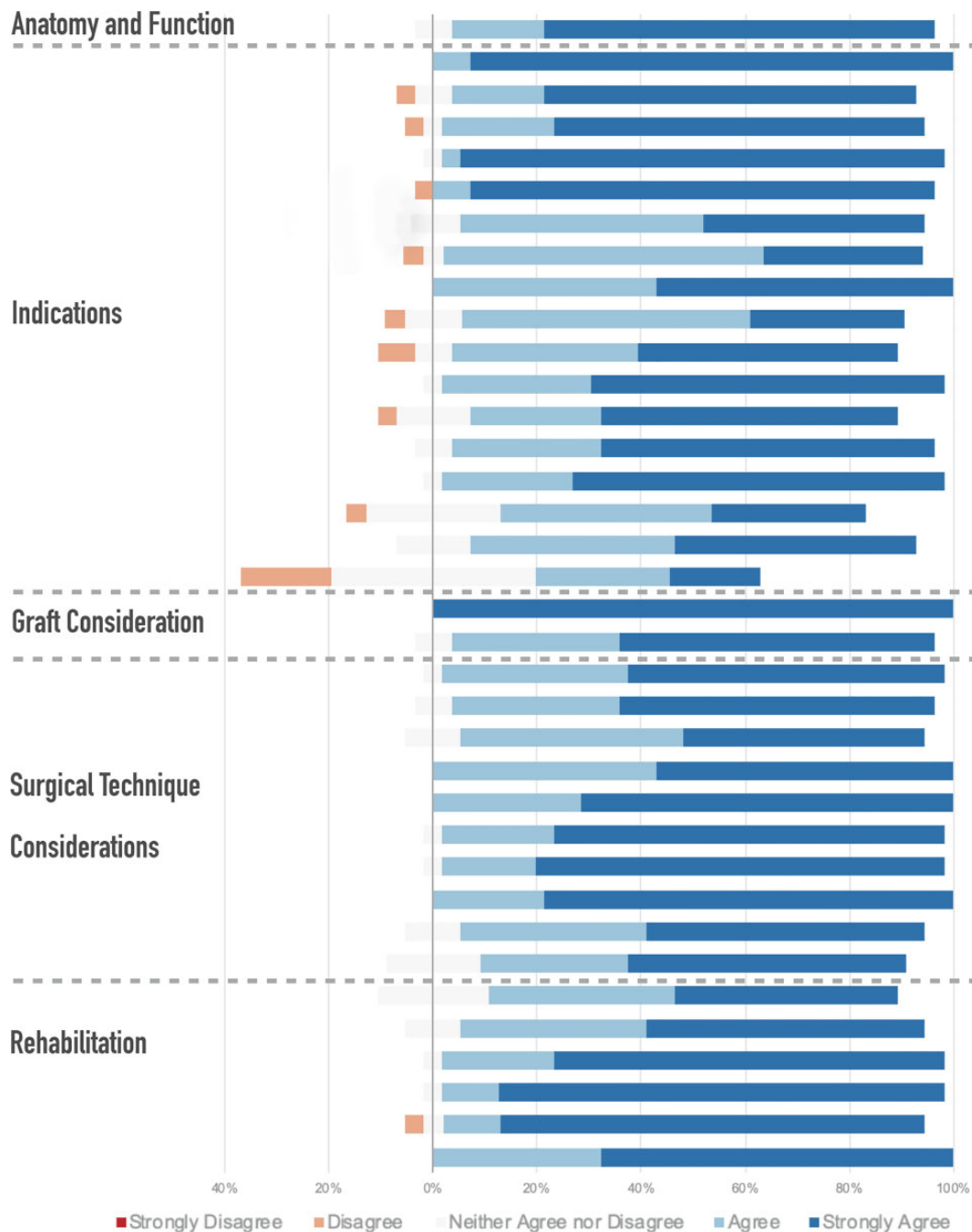
In the patellofemoral joint, morphology matching makes OCA technically more demanding than ACI. This is because of the complex topography, with highly variable shapes of the patella and trochlea. Furthermore, patients with patellofemoral cartilage lesions often have different morphology when compared with controls and potential donors.<sup>56</sup> This complicated morphology matching is more pronounced with the involvement of the central trochlear groove and median patellar ridge. Still, there was no agreement that ACI is preferred in those situations. With that being said, while OCA graft matching can be challenging in the patellofemoral joint, a consensus did not favor ACI in this setting.

## Graft and Surgical Technique Considerations

A consensus was reached in multiple surgical technical aspects and on donor graft considerations for osteochondral allografts. When performing OCA, grafts from the same location are preferred, and matching can be performed by radiography with a sizing marker or magnetic resonance

<sup>†</sup>References 4, 20, 25, 26, 32, 33, 35, 51, 52, 66, 70, 73, 76, 84, 87, 92.

<sup>#</sup>References 5, 16, 25, 34, 35, 37, 46, 57, 61, 63, 64, 68, 76, 85, 88.



**Figure 1.** Stacked leaning bar chart representing the breakdown in agreement levels in the third-round Delphi survey. Bars to the left of the y-axis indicate disagreement, with bars to the right indicating agreement.

imaging.<sup>8,19,23,47</sup> Location matching has been reported to improve the congruence between the graft and recipient surfaces.<sup>86</sup>

Experts agreed that chondrocyte viability is crucial to graft survival. To this point, the preservation technique (fresh grafts have greater chondrocyte viability than cryopreserved grafts),<sup>19,47</sup> timing (implantation in <28 days),<sup>2,6,95</sup> and technique of implantation (avoiding

impaction)<sup>9,71</sup> can significantly affect chondrocyte viability. In this regard, higher impact loads may be encountered when the graft is thicker than 10 mm and when there is a >2-mm difference between the graft and recipient hole, and thus, thinner plugs are now recommended that match the depth of the socket.<sup>71,91</sup> Laboratory studies demonstrated that high-impact loads adversely affect cell viability, with less than 50% to 70% of the cells remaining viable in that

setting.<sup>71,91</sup> The load of impact has a larger influence on chondrocyte death than the number of impacts. Thus, multiple low-load taps are preferred over single high-load taps if impaction cannot be avoided.<sup>94</sup> Therefore, the goal is to obtain a 6- to 10-mm graft that is flush with the cartilage surface and in contact with the bottom of the recipient hole, regardless of subchondral bone matching.<sup>\*\*</sup> This method decreases the subsidence of the graft and results in better restoration of the contact pressure in that compartment.<sup>49</sup>

Another subject of debate in the 3 rounds of the Delphi consensus was the treatment of uncontained lesions in the patellofemoral joint. Experts stated that patellofemoral chondral injuries can be treated with ACI and OCA with appropriate modifications to ensure stability. These can be performed with transosseous sutures or anchors in ACI; however, MACI might not need any additional fixation if the uncontained portion is small.<sup>25,34,35</sup> In certain situations, OCA might need additional fixation when the graft is unstable.<sup>10,13,37</sup> Headless metal screws or absorbable internal fixation materials can be used for fixation, with the acknowledgment that metal screws will need to be removed once the OCA site has healed.<sup>13,37</sup> Other surgical technical aspects that had agreement were that dowels are preferred compared with shell grafts when possible<sup>15</sup> and that pulse lavage should be used because it may decrease the concentration of bone marrow elements.<sup>44</sup>

## Rehabilitation

Last, a sequential, staged rehabilitation program (range of motion, muscular endurance, strength, and power) was felt to be essential for a successful outcome among experts.<sup>65</sup> In early phases, a comprehensive patellar and tibiofemoral mobilization protocol is safe and should be implemented to avoid arthrofibrosis.<sup>13,37,63</sup> Notably, progressive weight-bearing as tolerated with a knee brace locked in full extension does not excessively load the patellofemoral joint and is therefore considered safe if no associated osteotomy is performed.<sup>35,55,77</sup>

This expert consensus statement fulfills established criteria for the reporting of Delphi studies<sup>22</sup> using a validated number of experts.<sup>1</sup> The 100% response rate across all 3 survey rounds highlights the commitment of these experts to establish a consensus on the management of patellofemoral chondral injuries. The Delphi technique has additional strengths as well as preserving participants' anonymity and therefore shields participants from more influential expert opinions. Furthermore, the potential influence of any single participant was reduced by including more experts than most published Delphi studies. Last, the level of agreement required for final inclusion was higher than most health care Delphi studies<sup>22</sup> to ensure that only statements supported by over 95% of experts were included. Nevertheless, this study is not without limitations. As with any other consensus statement, although the statements were created from a review of the literature, the modifications and suggestions presented are not directly

derived from data but from expert opinions. Additional research, including clinical outcomes data, is required to validate this consensus statement.

## CONCLUSION

This study established a strong expert consensus document relating to the functional anatomy, surgical indications, donor graft considerations for osteochondral allografts, surgical technical aspects, and rehabilitation concepts for the management of large chondral and osteochondral defects in the patellofemoral joint. Further research is required to clinically validate the established consensus statements and better understand the precise indications for surgery as well as which techniques and graft processing/preparation methods should be used based on patient- and lesion-specific factors.

## AUTHORS

Jorge Chahla, MD, PhD (Midwest Orthopaedics at Rush, Chicago, Illinois, USA); Betina B. Hinckel, MD, PhD (Oakland University, Rochester, Michigan, USA; Department of Orthopaedic Surgery, William Beaumont Hospital, Royal Oak, Michigan, USA); Adam B. Yanke, MD, PhD (Midwest Orthopaedics at Rush, Chicago, Illinois, USA); Jack Farr, MD (OrthoIndy, Indianapolis, Indiana, USA); and Metrics of Osteochondral Allografts (MOCA) Group Collaborators: William D. Bugbee, MD, FAAOS (Shiley Center for Orthopaedic Research and Education, Scripps Clinic, La Jolla, California, USA); James L. Carey, MD, MPH (University of Pennsylvania, Philadelphia, Pennsylvania, USA); Brian J. Cole, MD, MBA, FAAOS (Midwest Orthopaedics at Rush, Chicago, Illinois, USA); Dennis C. Crawford, MD, PhD, FAAOS (Oregon Health & Science University, Portland, Oregon, USA); James E. Fleischli, MD, FAAOS (OrthoCarolina Sports Medicine Center, Charlotte, North Carolina, USA); Alan Getgood, MD, FRCS(Ortho) (Fowler Kennedy Sport Medicine Clinic, Western University, London, Ontario, Canada); Andreas H. Gomoll, MD, FAAOS (Hospital for Special Surgery, New York, New York, USA); Simon Gortz, MD (Brigham and Women's Hospital, Harvard Medical School, Boston, Massachusetts, USA); Allan E. Gross, MD, FRCSC (Mount Sinai Hospital, University of Toronto, Toronto, Ontario, Canada); Deryk G. Jones, MD, FAAOS (Ochsner Sports Medicine Institute, New Orleans, Louisiana, USA); Aaron J. Krych, MD, FAAOS (Mayo Clinic, Rochester, Minnesota, USA); Christian Lattermann, MD, FAAOS (Brigham and Women's Hospital, Harvard Medical School, Boston, Massachusetts, USA); Bert R. Mandelbaum, MD, FAAOS (Santa Monica Orthopaedic and Sports Medicine Group, Santa Monica, California, USA); Peter R. Mandt, MD, FAAOS (Proliance Orthopaedics & Sports Medicine, Issaquah, Washington, USA); Tom Minas, MD, MS, FACS, FRCS(C) (Paley Orthopedic & Spine Institute, West Palm Beach, Florida, USA); Raffy Mirzayan, MD, FAAOS (Kaiser Permanente, Baldwin Park, California, USA); Timothy S. Mologne, MD (Orthopedic & Sports

\*\*References 17, 43, 48, 50, 67, 72, 83, 90, 91.

Institute, Appleton, Wisconsin, USA); John D. Polousky, MD, FAAOS (Children's Health Andrews Institute for Orthopaedics & Sports Medicine, Plano, Texas, USA); Matthew T. Provencher, MD, Capt MC, USNR (Steadman Philippon Research Institute, Vail, Colorado, USA); Scott A. Rodeo, MD, FAAOS (Hospital for Special Surgery, New York, New York, USA); Oleg Safir, MD, FRCSC (Mount Sinai Hospital, University of Toronto, Toronto, Ontario, Canada); Seth Lawrence Sherman, MD (Department of Orthopaedic Surgery, Stanford University, Palo Alto, California, USA); Eric D. Strauss, MD, FAAOS (New York University Langone Health, New York, New York, USA); Sabrina M. Strickland, MD (Hospital for Special Surgery, New York, New York, USA); Christopher J. Wahl, MD, FAAOS (University of Washington, Seattle, Washington, USA); and Riley J. Williams III, MD, FAAOS (Hospital for Special Surgery, New York, New York, USA).

## REFERENCES

- Akins RB, Tolson H, Cole BR. Stability of response characteristics of a Delphi panel: application of bootstrap data expansion. *BMC Med Res Methodol.* 2005;5:37.
- Allen RT, Robertson CM, Pennock AT, et al. Analysis of stored osteochondral allografts at the time of surgical implantation. *Am J Sports Med.* 2005;33(10):1479-1484.
- Ambra LF, Hinckel BB, Arendt EA, Farr J, Gomoll AH. Anatomic risk factors for focal cartilage lesions in the patella and trochlea: a case-control study. *Am J Sports Med.* 2019;47(10):2444-2453.
- Astur DC, Arliani GG, Binz M, et al. Autologous osteochondral transplantation for treating patellar chondral injuries: evaluation, treatment, and outcomes of a two-year follow-up study. *J Bone Joint Surg Am.* 2014;96(10):816-823.
- Bakay A, Csonge L, Papp G, Fekete L. Osteochondral resurfacing of the knee joint with allograft: clinical analysis of 33 cases. *Int Orthop.* 1998;22(5):277-281.
- Ball ST, Amiel D, Williams SK, et al. The effects of storage on fresh human osteochondral allografts. *Clin Orthop Relat Res.* 2004;418:246-252.
- Beck PR, Thomas AL, Farr J, Lewis PB, Cole BJ. Trochlear contact pressures after anteromedialization of the tibial tubercle. *Am J Sports Med.* 2005;33(11):1710-1715.
- Bernstein DT, O'Neill CA, Kim RS, et al. Osteochondral allograft donor-host matching by the femoral condyle radius of curvature. *Am J Sports Med.* 2017;45(2):403-409.
- Borazjani BH, Chen AC, Bae WC, et al. Effect of impact on chondrocyte viability during insertion of human osteochondral grafts. *J Bone Joint Surg Am.* 2006;88(9):1934-1943.
- Bowland P, Ingham E, Jennings L, Fisher J. Review of the biomechanics and biotribology of osteochondral grafts used for surgical interventions in the knee. *Proc Inst Mech Eng H.* 2015;229(12):879-888.
- Brittberg M, Lindahl A, Nilsson A, Ohlsson C, Isaksson O, Peterson L. Treatment of deep cartilage defects in the knee with autologous chondrocyte transplantation. *N Engl J Med.* 1994;331(14):889-895.
- Brophy RH, Wojahn RD, Lamplot JD. Cartilage restoration techniques for the patellofemoral joint. *J Am Acad Orthop Surg.* 2017;25(5):321-329.
- Cameron JL, Pulido PA, McCauley JC, Bugbee WD. Osteochondral allograft transplantation of the femoral trochlea. *Am J Sports Med.* 2016;44(3):633-638.
- Chahla J, Murray IR, Robinson J, et al. Posterolateral corner of the knee: an expert consensus statement on diagnosis, classification, treatment, and rehabilitation. *Knee Surg Sports Traumatol Arthrosc.* 2019;27(8):2520-2529.
- Chahla J, Sweet MC, Okoroha KR, et al. Osteochondral allograft transplantation in the patellofemoral joint: a systematic review. *Am J Sports Med.* 2019;47(12):3009-3018.
- Chu CR, Convery FR, Akeson WH, Meyers M, Amiel D. Articular cartilage transplantation: clinical results in the knee. *Clin Orthop Relat Res.* 1999;360:159-168.
- Cohen ZA, McCarthy DM, Kwak SD, et al. Knee cartilage topography, thickness, and contact areas from MRI: in-vitro calibration and in-vivo measurements. *Osteoarthritis Cartilage.* 1999;7(1):95-109.
- Cotter EJ, Hannon CP, Christian DR, et al. Clinical outcomes of multifocal osteochondral allograft transplantation of the knee: an analysis of overlapping grafts and multifocal lesions. *Am J Sports Med.* 2018;46(12):2884-2893.
- Csonge L, Bravo D, Newman-Gage H, et al. Banking of osteochondral allografts, part II: preservation of chondrocyte viability during long-term storage. *Cell Tissue Bank.* 2002;3(3):161-168.
- Cvetanovich GL, Riboh JC, Tilton AK, Cole BJ. Autologous chondrocyte implantation improves knee-specific functional outcomes and health-related quality of life in adolescent patients. *Am J Sports Med.* 2017;45(1):70-76.
- Demange MK, Minas T, von Keudell A, Sodha S, Bryant T, Gomoll AH. Intralesional osteophyte regrowth following autologous chondrocyte implantation after previous treatment with marrow stimulation technique. *Cartilage.* 2017;8(2):131-138.
- Diamond IR, Grant RC, Feldman BM, et al. Defining consensus: a systematic review recommends methodologic criteria for reporting of Delphi studies. *J Clin Epidemiol.* 2014;67(4):401-409.
- Du PZ, Markolf KL, Levine BD, McAllister DR, Jones KJ. Differences in the radius of curvature between femoral condyles: implications for osteochondral allograft matching. *J Bone Joint Surg Am.* 2018;100(15):1326-1331.
- Familiari F, Cinque ME, Chahla J, et al. Clinical outcomes and failure rates of osteochondral allograft transplantation in the knee: a systematic review. *Am J Sports Med.* 2018;46(14):3541-3549.
- Farr J. Autologous chondrocyte implantation improves patellofemoral cartilage treatment outcomes. *Clin Orthop Relat Res.* 2007;463:187-194.
- Filardo G, Kon E, Andriolo L, Di Martino A, Zaffagnini S, Marcacci M. Treatment of "patellofemoral" cartilage lesions with matrix-assisted autologous chondrocyte transplantation: a comparison of patellar and trochlear lesions. *Am J Sports Med.* 2014;42(3):626-634.
- Filardo G, Vannini F, Marcacci M, et al. Matrix-assisted autologous chondrocyte transplantation for cartilage regeneration in osteoarthritic knees: results and failures at midterm follow-up. *Am J Sports Med.* 2013;41(1):95-100.
- Flynn TW, Soutas-Little RW. Patellofemoral joint compressive forces in forward and backward running. *J Orthop Sports Phys Ther.* 1995;21(5):277-282.
- Frank RM, Lee S, Levy D, et al. Osteochondral allograft transplantation of the knee: analysis of failures at 5 years. *Am J Sports Med.* 2017;45(4):864-874.
- Giannini S, Buda R, Ruffilli A, et al. Failures in bipolar fresh osteochondral allograft for the treatment of end-stage knee osteoarthritis. *Knee Surg Sports Traumatol Arthrosc.* 2015;23(7):2081-2089.
- Gillgoly SD. Treatment of large full-thickness chondral defects of the knee with autologous chondrocyte implantation. *Arthroscopy.* 2003;19(suppl 1):147-153.
- Gillgoly SD, Arnold RM. Autologous chondrocyte implantation and anteromedialization for isolated patellar articular cartilage lesions: 5- to 11-year follow-up. *Am J Sports Med.* 2014;42(4):912-920.
- Gobbi A, Chaurasia S, Karnatzikos G, Nakamura N. Matrix-induced autologous chondrocyte implantation versus multipotent stem cells for the treatment of large patellofemoral chondral lesions: a nonrandomized prospective trial. *Cartilage.* 2015;6(2):82-97.
- Gomoll AH, Ambra LF, Phan A, Mastrocola M, Shah N. Cell-seeded autologous chondrocyte implantation: a simplified implantation technique that maintains high clinical outcomes. *Am J Sports Med.* 2017;45(5):1028-1036.



35. Gomoll AH, Gillogly SD, Cole BJ, et al. Autologous chondrocyte implantation in the patella: a multicenter experience. *Am J Sports Med.* 2014;42(5):1074-1081.
36. Gracitelli GC, Meric G, Briggs DT, et al. Fresh osteochondral allografts in the knee: comparison of primary transplantation versus transplantation after failure of previous subchondral marrow stimulation. *Am J Sports Med.* 2015;43(4):885-891.
37. Gracitelli GC, Meric G, Pulido PA, Gortz S, De Young AJ, Bugbee WD. Fresh osteochondral allograft transplantation for isolated patellar cartilage injury. *Am J Sports Med.* 2015;43(4):879-884.
38. Gracitelli GC, Meric G, Pulido PA, McCauley JC, Bugbee WD. Osteochondral allograft transplantation for knee lesions after failure of cartilage repair surgery. *Cartilage.* 2015;6(2):98-105.
39. Greenhalgh T, Wong G, Jagosh J, et al. Protocol—the RAMESES II study: developing guidance and reporting standards for realist evaluation. *BMJ Open.* 2015;5(8):e008567.
40. Hinckel BB, Gomoll AH. Autologous chondrocytes and next-generation matrix-based autologous chondrocyte implantation. *Clin Sports Med.* 2017;36(3):525-548.
41. Hinckel BB, Gomoll AH. Patellofemoral cartilage restoration: indications, techniques, and outcomes of autologous chondrocytes implantation, matrix-induced chondrocyte implantation, and particulated juvenile allograft cartilage. *J Knee Surg.* 2018;31(3):212-226.
42. Holliday C, Robotin M. The Delphi process: a solution for reviewing novel grant applications. *Int J Gen Med.* 2010;3:225-230.
43. Huang FS, Simonian PT, Norman AG, Clark JM. Effects of small incongruities in a sheep model of osteochondral autografting. *Am J Sports Med.* 2004;32(8):1842-1848.
44. Ibrahim T, Qureshi A, McQuillan TA, Thomson J, Galea G, Power RA. Intra-operative washing of morcellised bone allograft with pulse lavage: how effective is it in reducing blood and marrow content? *Cell Tissue Bank.* 2012;13(1):157-165.
45. Jakob RP, Franz T, Gautier E, Mainil-Varlet P. Autologous osteochondral grafting in the knee: indication, results, and reflections. *Clin Orthop Relat Res.* 2002;401:170-184.
46. Jamali AA, Emmerson BC, Chung C, Convery FR, Bugbee WD. Fresh osteochondral allografts: results in the patellofemoral joint. *Clin Orthop Relat Res.* 2005;437:176-185.
47. Jomha NM, Lavoie G, Muldrew K, Schachar NS, McGann LE. Cryopreservation of intact human articular cartilage. *J Orthop Res.* 2002;20(6):1253-1255.
48. Kock NB, Hannink G, van Kampen A, Verdonshot N, van Susante JL, Buma P. Evaluation of subsidence, chondrocyte survival and graft incorporation following autologous osteochondral transplantation. *Knee Surg Sports Traumatol Arthrosc.* 2011;19(11):1962-1970.
49. Kock NB, Smolders JM, van Susante JL, Buma P, van Kampen A, Verdonshot N. A cadaveric analysis of contact stress restoration after osteochondral transplantation of a cylindrical cartilage defect. *Knee Surg Sports Traumatol Arthrosc.* 2008;16(5):461-468.
50. Koh JL, Wirsing K, Lautenschlager E, Zhang LO. The effect of graft height mismatch on contact pressure following osteochondral grafting: a biomechanical study. *Am J Sports Med.* 2004;32(2):317-320.
51. Kon E, Filardo G, Gobbi A, et al. Long-term results after hyaluronan-based MACT for the treatment of cartilage lesions of the patellofemoral joint. *Am J Sports Med.* 2016;44(3):602-608.
52. Kreuz PC, Muller S, von Keudell A, et al. Influence of sex on the outcome of autologous chondrocyte implantation in chondral defects of the knee. *Am J Sports Med.* 2013;41(7):1541-1548.
53. Likert R. A technique for the measurement of attitudes. *Arch Psychol.* 1932;140:1-55.
54. Liu JN, Wu HH, Garcia GH, Kalbian IL, Strickland SM, Shubin Stein BE. Return to sports after tibial tubercle osteotomy for patellofemoral pain and osteoarthritis. *Arthroscopy.* 2018;34(4):1022-1029.
55. Loudon JK. Biomechanics and pathomechanics of the patellofemoral joint. *Int J Sports Phys Ther.* 2016;11(6):820-830.
56. Mehl J, Feucht MJ, Bode G, Dovi-Akue D, Sudkamp NP, Niemeyer P. Association between patellar cartilage defects and patellofemoral geometry: a matched-pair MRI comparison of patients with and without isolated patellar cartilage defects. *Knee Surg Sports Traumatol Arthrosc.* 2016;24(3):838-846.
57. Meric G, Gracitelli GC, Gortz S, De Young AJ, Bugbee WD. Fresh osteochondral allograft transplantation for bipolar reciprocal osteochondral lesions of the knee. *Am J Sports Med.* 2015;43(3):709-714.
58. Meyer MA, McCarthy MA, Gitelis ME, et al. Effectiveness of lavage techniques in removing immunogenic elements from osteochondral allografts. *Cartilage.* 2017;8(4):369-373.
59. Minas T, Bryant T. The role of autologous chondrocyte implantation in the patellofemoral joint. *Clin Orthop Relat Res.* 2005;436:30-39.
60. Minas T, Gomoll AH, Rosenberger R, Royce RO, Bryant T. Increased failure rate of autologous chondrocyte implantation after previous treatment with marrow stimulation techniques. *Am J Sports Med.* 2009;37(5):902-908.
61. Minas T, Gomoll AH, Solhpour S, Rosenberger R, Probst C, Bryant T. Autologous chondrocyte implantation for joint preservation in patients with early osteoarthritis. *Clin Orthop Relat Res.* 2010;468(1):147-157.
62. Minas T, Ogura T, Headrick J, Bryant T. Autologous chondrocyte implantation “sandwich” technique compared with autologous bone grafting for deep osteochondral lesions in the knee. *Am J Sports Med.* 2018;46(2):322-332.
63. Minas T, Von Keudell A, Bryant T, Gomoll AH. The John Insall Award: a minimum 10-year outcome study of autologous chondrocyte implantation. *Clin Orthop Relat Res.* 2014;472(1):41-51.
64. Mirzayan R, Charles MD, Batech M, Suh BD, DeWitt D. Bipolar osteochondral allograft transplantation of the patella and trochlea [published online September 3, 2018]. *Cartilage.* doi:10.1177/1947603518796124
65. Mithoefer K, Hambly K, Logerstedt D, Ricci M, Silvers H, Della Villa S. Current concepts for rehabilitation and return to sport after knee articular cartilage repair in the athlete. *J Orthop Sports Phys Ther.* 2012;42(3):254-273.
66. Niemeyer P, Steinwachs M, Erggelet C, et al. Autologous chondrocyte implantation for the treatment of retropatellar cartilage defects: clinical results referred to defect localisation. *Arch Orthop Trauma Surg.* 2008;128(11):1223-1231.
67. Nosewicz TL, Reilingh ML, Wolny M, van Dijk CN, Duda GN, Schell H. Influence of basal support and early loading on bone cartilage healing in press-fitted osteochondral autografts. *Knee Surg Sports Traumatol Arthrosc.* 2014;22(6):1445-1451.
68. Ogura T, Bryant T, Merkely G, Minas T. Autologous chondrocyte implantation for bipolar chondral lesions in the patellofemoral compartment: clinical outcomes at a mean 9 years' follow-up. *Am J Sports Med.* 2019;47(4):837-846.
69. Pareek A, Carey JL, Reardon PJ, Peterson L, Stuart MJ, Krych AJ. Long-term outcomes after autologous chondrocyte implantation: a systematic review at mean follow-up of 11.4 years. *Cartilage.* 2016;7(4):298-308.
70. Pascual-Garrido C, Slabaugh MA, L'Heureux DR, Friel NA, Cole BJ. Recommendations and treatment outcomes for patellofemoral articular cartilage defects with autologous chondrocyte implantation: prospective evaluation at average 4-year follow-up. *Am J Sports Med.* 2009;37(suppl 1):33S-41S.
71. Patil S, Butcher W, D'Lima DD, Steklov N, Bugbee WD, Hoenecke HR. Effect of osteochondral graft insertion forces on chondrocyte viability. *Am J Sports Med.* 2008;36(9):1726-1732.
72. Pearce SG, Hurtig MB, Clarnette R, Kalra M, Cowan B, Miniaci A. An investigation of 2 techniques for optimizing joint surface congruency using multiple cylindrical osteochondral autografts. *Arthroscopy.* 2001;17(1):50-55.
73. Perdisa F, Filardo G, Sessa A, et al. One-step treatment for patellar cartilage defects with a cell-free osteochondral scaffold. *Am J Sports Med.* 2017;45(7):1581-1588.
74. Peterson L, Brittberg M, Kiviranta I, Akerlund EL, Lindahl A. Autologous chondrocyte transplantation: biomechanics and long-term durability. *Am J Sports Med.* 2002;30(1):2-12.

75. Peterson L, Minas T, Brittberg M, Lindahl A. Treatment of osteochondritis dissecans of the knee with autologous chondrocyte transplantation: results at two to ten years. *J Bone Joint Surg Am.* 2003;85(suppl 2):17-24.
76. Peterson L, Vasiliadis HS, Brittberg M, Lindahl A. Autologous chondrocyte implantation: a long-term follow-up. *Am J Sports Med.* 2010;38(6):1117-1124.
77. Rosso F, Rossi R, Governale G, et al. Tibial tuberosity anteromedialization for patellofemoral chondral disease: prognostic factors. *Am J Sports Med.* 2017;45(7):1589-1598.
78. Rue JP, Colton A, Zare SM, et al. Trochlear contact pressures after straight anteriorization of the tibial tuberosity. *Am J Sports Med.* 2008;36(10):1953-1959.
79. Sanders TL, Pareek A, Obey MR, et al. High rate of osteoarthritis after osteochondritis dissecans fragment excision compared with surgical restoration at a mean 16-year follow-up. *Am J Sports Med.* 2017;45(8):1799-1805.
80. Shanmugaraj A, Coughlin RP, Kuper GN, et al. Changing trends in the use of cartilage restoration techniques for the patellofemoral joint: a systematic review. *Knee Surg Sports Traumatol Arthrosc.* 2019;27(3):854-867.
81. Siebold R, Karidakis G, Fernandez F. Clinical outcome after medial patellofemoral ligament reconstruction and autologous chondrocyte implantation following recurrent patella dislocation. *Knee Surg Sports Traumatol Arthrosc.* 2014;22(10):2477-2483.
82. Stacey D, Bennett CL, Barry MJ, et al. Decision aids for people facing health treatment or screening decisions. *Cochrane Database Syst Rev.* 2011;10:CD001431.
83. Thaunat M, Couchon S, Lunn J, Charrois O, Fallet L, Beaufile P. Cartilage thickness matching of selected donor and recipient sites for osteochondral autografting of the medial femoral condyle. *Knee Surg Sports Traumatol Arthrosc.* 2007;15(4):381-386.
84. Tompkins M, Hamann JC, Diduch DR, et al. Preliminary results of a novel single-stage cartilage restoration technique: particulated juvenile articular cartilage allograft for chondral defects of the patella. *Arthroscopy.* 2013;29(10):1661-1670.
85. Torga Spak R, Teitge RA. Fresh osteochondral allografts for patellofemoral arthritis: long-term followup. *Clin Orthop Relat Res.* 2006;444:193-200.
86. Urita A, Cvetanovich GL, Madden BT, et al. Topographic matching of osteochondral allograft transplantation using lateral femoral condyle for the treatment of medial femoral condyle lesions: a computer-simulated model study. *Arthroscopy.* 2018;34(11):3033-3042.
87. Vanlauwe JJ, Claes T, Van Assche D, Bellemans J, Luyten FP. Characterized chondrocyte implantation in the patellofemoral joint: an up to 4-year follow-up of a prospective cohort of 38 patients. *Am J Sports Med.* 2012;40(8):1799-1807.
88. Vasiliadis HS, Lindahl A, Georgoulis AD, Peterson L. Malalignment and cartilage lesions in the patellofemoral joint treated with autologous chondrocyte implantation. *Knee Surg Sports Traumatol Arthrosc.* 2011;19(3):452-457.
89. von Keudell A, Han R, Bryant T, Minas T. Autologous chondrocyte implantation to isolated patella cartilage defects. *Cartilage.* 2017;8(2):146-154.
90. von Rechenberg B, Akens MK, Nadler D, et al. Changes in subchondral bone in cartilage resurfacing: an experimental study in sheep using different types of osteochondral grafts. *Osteoarthritis Cartilage.* 2003;11(4):265-277.
91. Walczak BE, Nies MS, Trask DJ, et al. Osteochondral graft size is significantly associated with increased force and decreased chondrocyte viability. *Am J Sports Med.* 2018;46(3):623-631.
92. Wang T, Belkin NS, Burge AJ, et al. Patellofemoral cartilage lesions treated with particulated juvenile allograft cartilage: a prospective study with minimum 2-year clinical and magnetic resonance imaging outcomes. *Arthroscopy.* 2018;34(5):1498-1505.
93. Washington DL, Bernstein SJ, Kahan JP, Leape LL, Kamberg CJ, Shekelle PG. Reliability of clinical guideline development using mail-only versus in-person expert panels. *Med Care.* 2003;41(12):1374-1381.
94. Whiteside RA, Jakob RP, Wyss UP, Mainil-Varlet P. Impact loading of articular cartilage during transplantation of osteochondral autograft. *J Bone Joint Surg Br.* 2005;87(9):1285-1291.
95. Williams SK, Amiel D, Ball ST, et al. Prolonged storage effects on the articular cartilage of fresh human osteochondral allografts. *J Bone Joint Surg Am.* 2003;85(11):2111-2120.